

Effectiveness of Intra articular Injection of Platelet-Rich Plasma in Patients with Anterior Disc Displacement with Reduction

Farah Taha A. Alhussien B.D.S., MSc⁽¹⁾

Ameena Ryhan M.Sc.Ph.D (Oral Medicine)⁽²⁾

ABSTRACT

Background: Anterior disc displacement with reduction (ADDWR) is the most common form of the internal derangement (ID) of temporomandibular joint (TMJ). It is a painful progressive dysfunction and clinically characterized by reciprocal clicking due to shift in the disc anteriorly in relation to the condyle and fossa during mandible elevation. Minimally invasive therapy such as intra-articular injection of platelet-rich plasma (PRP) has been used. PRP is a natural autologous product with a high platelet concentration obtained by centrifugation process to enhance tissue healing through several growth factors (GFs), which are released after endogenous activation. The aim of this study is to assess this technique which is increasingly used today as a safe, simple modality.

Materials and Methods: sixty patients with ADDWR were participated (Females 41, males 19; age 20-39 years). Patients were divided into two groups; PRP was used as study group and conservative therapy was used as control group. 1 ml of PRP was obtained by a single step centrifugation. Pain, joint sounds and maximum mouth opening were clinically evaluated before and two months after therapy.

Results: There was statistically significant improvement in pain score, clicking and maximum mouth opening in patients treated with PRP. No complications were recorded immediately and two months after therapy.

Conclusion: This study support the effectiveness of PRP injection in treatment of ADDWR as a safe modality in reducing pain, clicking and increase mouth opening.

Key words: Articular disc, Conservative, Intra-articular injection, Platelet-rich plasma. (J Bagh Coll Dentistry 2017; 29(4): 44-52)

INTRODUCTION:

Anterior disc displacement with reduction (ADDWR) is an abnormal relationship between disc, condyle, and the articular eminence, due to elongation or tearing of the attachments between disc, condyle and glenoid fossa⁽¹⁾. It is one of the most frequent cause of Temporomandibular disorders (TMDs)⁽¹⁾. Chronic micro-trauma is the most important etiological factor of ADDWR, resulting from longstanding bruxism or clenching of teeth or from direct trauma to the joint⁽²⁾. The principal goal of the therapeutic management for ADDWR is to relief pain, preserve normal range of motion and prevent excessive joint damage⁽³⁾. Many conservative methods suggested for ADDWR including patient education and self-care, physical, intraoral appliance therapy and pharmacotherapy that should be initially used before any invasive treatment⁽³⁾.

Platelet-rich plasma (PRP) is a blood derivative of high platelet concentration compared to the whole blood⁽⁴⁾. It has been used in the treatment of ADDWR⁽⁴⁾, because of its influence on the entire joint environment and produces a good therapeutic effect in patients with clicking, pain and limitation in mouth opening⁽⁵⁾. It may be obtained through a simple and unexpensive technique via withdrawal and centrifugation of a sample of patients own blood. PRP contain high number of GFs in alpha granules, which when activated endogenously, a cluster of GFs and biologically active molecules were released, were which found to have an anti-inflammatory, antibacterial and analgesic properties⁽⁶⁾.

MATERIALS AND METHODS

The subjects:

Sixty Iraqi patients (41 females and 19 males) were participated in this prospective study, with their age range was between 20-40 years, they were divided into two groups; first group were thirty patients who had ADDWR, who did not respond to a previous conservative therapy, thus received PRP injection(study group). The second group were also thirty patients who received a conservative treatment and was considered as a control group. All participants attended to the

1) Master Student, Oral medicine, Department of Oral Diagnosis, College of Dentistry/ University of Baghdad, Iraq

2) Assistant Professor, Department of Oral Diagnosis Oral Medicine College of Dentistry, University of Baghdad.

Maxillofacial Department of Al-Yarmouk Teaching Hospital during the period from November 2015 to May 2016, were asked to take part in this study. Patients were informed about the study aims and objectives and given their written consent form before participating in the study. Patients with pain in temporomandibular joints, limitation in mouth opening and clicking were included in this study while patients with thrombocytopenia or any platelet dysfunction, patients who had inflammatory or connective tissue disease, patients who received anticoagulant medications, patients with tumor or premalignant lesion at the site of procedure, patients with possible compromised immune system and pregnancy were excluded from this study.

Clinical assessment:

The patients assessed their pain intensity using visual analog scale (VAS) from 0: no pain to 10: the worst imaginable pain. Noise within joint movement was assessed through palpation and maximal interincisal opening (MIO) was clinically measured and recorded in millimeters.

All these assessments were performed prior to PRP injection, then 1 and 2 month after injection.

Platelet- Rich Plasma Preparation

A. Blood collection:

Using 10 ml syringe gauge 21, eight milliliters of autologous venous blood sample was taken from antecubital vein. The blood sample then was drawn into PRP vacuum tube containing acid citrate dextrose (ACD-A) as an anticoagulant agent.

B. the centrifugation.

The procedure of PRP preparation was performed according to Mazzocca et al.,⁽⁷⁾

1. After blood sample collection, gently mixing the blood in PRP tube.
2. Centrifuge the PRP tube at 3000 rpm for 9-10 minute by placing another tube in the opposite side with the same weight, containing normal saline for balancing.
3. After centrifugation, the buffy coat layer is located on the upper surface of the visible gel and the red blood cells located on the bottom. Never open the PRP tube, discard 2/3 from the platelet poor plasma (PPP) by using spinal needle gauge 22.
4. Leave the tube in the rack for at least 15 minutes to insure the re-attachment of the hydrogen bonding in silica matrix gel to avoid the breakdown of gel.

5. Gently, mixing the remaining plasma with the buffy coat to insure dissolving all the buffy coat platelet which is located over the visible gel.
6. Aspirate the PRP by using a sterile 1 ml syringe with spinal needle (avoid touching the gel by needle).
7. Discard the needle and use a new needle with gauge 23; PRP process is ready for injection.

PRP Injection Therapy and Patient Follow-up:

Patient indicated for PRP was prepared by drawing a line from the middle tragus of the ear to the corner of the eye to determine the injection point, which is located along the line; 10 mm forward from the middle tragus and 2 mm below the line^(8,9). Firstly, TMJ region was washed with an antiseptic solution to decontaminate the field. Then the patient was asked to open his/her mouth half opening and the pre-aueicular concavity was formed at the marking point of the injection. One ml of PRP was injected into the superior joint space with the needle being directed medially and slightly antero-superiorly until a contact with glenoid fossa was achieved⁽¹⁰⁾. After PRP injection into the joint space, the needle then withdrawn and the skin disinfected again⁽¹⁰⁾. According to Di Matteo *et al*,⁽¹⁰⁾ the patient was asked to open and close his/her mouth several times for a minute to ensure equal distribution of PRP in the joint space. Patient informed about the possibility of experiencing an unpleasant sensation of fullness or compression and mild pain in the joint region, which may be resolved by itself within a period of a week without an intervention. A soft diet was advised for two weeks after the PRP injection.

Anti-inflammatory medications were not advised in order to avoid the analgesic effect of the medication during the documentation of pain relief period⁽¹¹⁾. Patient's follow-up was performed, one and two months after PRP injection to assess the patient pain, range of mouth opening and TMJ sounds⁽¹²⁾. During the follow up period, all post-operative complications and adverse effects were recorded if present.

Statistical analysis:

Data were analyzed using SPSS (statistical package for social sciences) version 22 software package. Continuous variables presented as means with standard deviation, discrete variables presented as numbers and percentages. T test was used to test the significance of observed differences in mean of two independent samples. Chi square test was used to test the significance of

association between discrete variables. T test for paired samples was used to test the significance of observed differences in mean of two independent samples. Findings with P value less than 0.05 were considered significant.

Results:

A total of sixty Iraqi patients were in rolled in this study. Considering PRP group of patients, 67% (20) were females and 33% (10) were males. In conservatively treated group of patients, 70% (21) were females and 30% (9) were males. The age range of patients was from 20-39 years with a mean of 30.4 years (SD: ±6.8).

Considering pain intensity, at the first presentation, pain intensity in PRP patients was found to be from 2-10 with a mean of 7.1 (SD: ±2.0), while pain intensity in conservatively treated patients was found to be from 3-10 with a mean of 6.0 (SD: ±1.8). A significant difference in pain intensity between PRP and conservatively treated patients was found at presentation time; PRP patients showed a higher mean of pain intensity (P < 0.030). After PRP therapy, at the end of the first month, PRP patients pain intensity was from 0-8 with a mean of 1.5 (SD: ±2.6), while pain intensity of the conservatively treated patients was from 0-5 with a mean of 0.8(SD: ±2.6). At the end of the second

month, PRP patient’s pain intensity was from 0-8 with a mean of 1.5 (SD: ±2.6). Pain intensity in conservatively treated group was from 0-8 with a mean of 4.6 (SD: ±2.5). A significant difference in pain intensity between both groups was found (at the end of 2nd month); PRP patients showed lower means of pain intensity compared to the control group (P < 0.001) (Figure1)

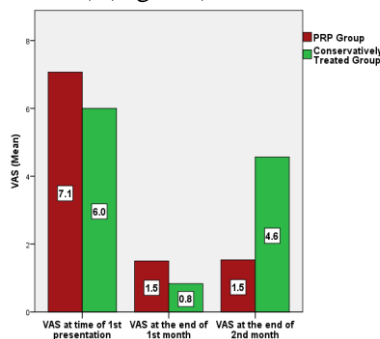


Fig 1: Visual Analogue Scale Mean of Study Population at Different Time Points.

The quality of pain improvement was assessed at the last follow-up appointment of patients (at the end of the 2nd month). The VAS score for pain

improved significantly in PRP patients (P<0.001); 93% of patients showed a significant reduction in pain at the TMJ region compared to only 40% of the control group who showed a pain reduction improvement.

Regarding TMJ clicking, All PRP and conservatively treated patients were presented with clicking at 1st presentation. At the end of the 1st month, only 10% of PRP patients showed disappearance of clicking, 73% showed decrease in clicking frequency, while the rest of patients (17%) experienced no changes in their clicking sounds. At the end of the second month, only 3% of PRP patients showed disappearance of clicking, 70% showed reduction in clicking frequency and 27% showed no changes in their clicking sound.

Statically, No significant difference was found in relation to clicking within PRP group of patients (P>0.05).

On the topic of the mouth opening, in PRP patients, the range of mouth opening without pain was from 12 to 35 mm with a mean of 24mm (SD: ±5.3). Following PRP therapy, the range of the mouth opening without pain was from 15-39 with a mean of 27.8 mm (SD: ±5.1) at the end of the first month. At the end of the second month, the range of mouth opening without pain was from 18-43 mm with a mean of 31.8 mm (SD: ±5.2)

Regarding conservatively treated patients, at the first presentation, the range of mouth opening without pain was from 18-49 mm with a mean of 31.9 mm (SD: ±8.0). At the end of the 1st month, the range of the mouth opening without pain was from 20-29 with a mean of 35.5 mm (SD: ±6.3). At the end of the 2nd month, the range of the mouth opening without pain was from 21-50 mm with a mean of 35.0 mm (SD: ±6.3). Statically, a significant differences were found between both groups at the first presentation & at the end of the 1st, 2nd month; PRP patients showed a lower mean of the mouth opening compared to the conservatively treated patients (P < 0.001, P < 0.001, P < 0.041).Table 1

Table 1: Range and Mean of Mouth Opening at Presentation and Two Months after PRP Therapy.

Variables	PRP patients (mm)	Conservatively treated patients (mm)	P value
-----------	-------------------	--------------------------------------	---------

First presentation	Range	12-35	18-49	<0.001
	Mean \pm SD	24 \pm 5.3	31.9 \pm 8.0	
End of the 1st month	Range	15-39	20-49	<0.001
	Mean \pm SD	27.8 \pm 5.1	35.5 \pm 6.3	
End of the 2nd month	Range	18-43	21-50	0.041
	Mean \pm SD	31.8 \pm 5.2	35.0 \pm 6.6	

Discussion:

The present study was conducted to investigate the effectiveness of PRP injection as a biological approach in the treatment of TMJ disorders with respect to pain, clicking and mouth opening in patients with anterior disc displacement with reduction.

Demography of Patients:

Age

In this study, the mean age of patients was 30.4 years which is in line with the fact that the age group between 20-40 years have a greater risk for developing TMD than others⁽¹³⁾. This may be related to stress factors, quality of life which has a direct influence on the prevalence of TMD⁽¹⁴⁾. While in advancing age, signs and symptoms become less or undetectable⁽¹⁵⁾. These results are in agreement with Marcelo *et al.*⁽¹⁶⁾ who studied the severity of TMD in relation to age and they found that there is no correlation between age and the severity of TMD; however there was a trend of greater severity of TMD in young adults (25-50 years).

Gender

In this study, females were more common than males in both PRP and conservatively treated patients. This can be explained by the fact that female patients may suffer from high level of pain and dysfunction and longer persistence of symptoms over a long duration of time due to the hormonal, behavioral and psychological problems⁽¹⁷⁾. Females have a 3-folds higher risk to develop TMD than males, according to studies conducted by Velly *et al.*⁽¹⁸⁾ and Marcelo *et al.*⁽¹⁶⁾; both studies showed that there is a greater involvement and increase expression of signs and symptoms in females than males. This result is in the line with Steven *et al.*⁽¹⁹⁾ study who showed that the functional estrogen receptors have been identified in females TMJs but not in males TMJs. Estrogen

may also promote degenerative changes in the TMJ by increasing the synthesis of specific cytokines, whereas testosterone may inhibit these cytokines⁽²⁰⁾.

TMJ Pain-Visual Analogue Scale (VAS)

In the present study, VAS scale was used to determine the pain intensity which was recorded at three time-points. A significant reduction in the mean pain intensity was recorded at the 1st follow-up after PRP therapy. This is supported by a study conducted by Hanci *et al.*⁽²¹⁾ who reported a pain reduction in 20 cases of TMJ dysfunction treated with PRP. Also this result is in line with a comparative study done by Sanchez *et al.*⁽²²⁾ on 60 patients with knee osteoarthritis; 30 of them were treated with PRP injection and 30 with hyaluronic acid. After 5 weeks, there were a better efficacy in pain reduction and subsequent improvement in joint function in PRP group.

Similarly, Sampson *et al.*⁽²³⁾ noted a reduction in pain and disease improvement in 14 patients with knee osteoarthritis in 6-months follow-up.

Current study is in consistent with a study conducted by Filardo *et al.*⁽²⁴⁾ who reported a significant pain reduction in 91 patients with chronic degeneration of knee in 12 months follow-up study; similar results were seen by Kon *et al.*⁽²⁵⁾ and Napolitano *et al.*⁽²⁶⁾ who recorded a noticeable pain reduction in 150 and 27 patients respectively treated with PRP for osteoarthritis of the knee joints.

Lee *et al.*⁽²⁷⁾ examined the role of PRP as an analgesic compound through adding PRP to a culture of chondrocyte leading to direct increase in mRNA levels of cannabinoid receptors CB1 and CB2, which has both analgesic and anti-inflammatory effects.

It is well known that pain of TMJ is mostly associated with changes in the biochemical components of the synovial fluid or alteration in intra-articular pressure in the joint environment rather than changes in disc position⁽²⁸⁾. After PRP application, the flow of chemical mediators to the microenvironment of the joint area via the GFs that derived from the alpha granule⁽²⁹⁾. Also PRP has an inflammatory modulating capability by eliminating pain inducers and providing a micro environmental repair of disc, capsule and retrodiscal pad; which may produce a symptomatic relief of pain in PRP-injected patients⁽²⁹⁾. Pietrzak and Eppley⁽³⁰⁾ stated that increased concentration of GFs which simulate the initial stage of the inflammatory response by the migration of

neutrophils, monocytes and macrophages to the site of injury⁽³⁰⁾. Furthermore, the cytokines and mediators may mediate the initiation of neovascularization, fibroblast proliferation and further recruitment of inflammatory cells⁽³⁰⁾. In addition to the stimulatory effects of PRP on reparative cells, the local delivery of PRP may have an inhibitory effect on specific pro-inflammatory cytokines, such as suppression of interleukin-1 that is released from the activated macrophages⁽³¹⁾. This dual action may improve the repair and reduce the tissue breakdown and may also permit the acceleration of tissue healing process and provide potential benefits for better outcomes and faster recovery⁽³²⁾.

TMJ Clicking

In this study, the high success rate of TMJ sound reduction is in line with a study performed by Hanci *et al.*⁽²¹⁾ who reported a significant reduction in joint sound after intra-articular injection of PRP in 20 patients out of 32 patients aged 26 years.

According to Anitua *et al.*⁽³³⁾, intra-articular administration of PRP may improve joint lubrication. Growth factors that are secreted from PRP may modulate synovial cell biology and increase secretion of hyaluronic acid⁽³³⁾, which is the most important component of synovial fluid⁽³⁴⁾, and supply all the rheological properties of the fluid⁽³⁵⁾. Hyaluronic acid have a multiple function, in addition of being a moisturizer agent for cartilage protection, it is also considered as space filler⁽³⁵⁾ and it acts as scavenger which inhibits the phagocytosis and chemotaxis; thus aid to preserve the joint integrity⁽³⁶⁾. Several in vitro studies conducted by Nitzan *et al.*⁽³⁷⁾ suggested that hyaluronic acid seems to have an indirect role in the boundary mechanism which is one of the lubrication mechanism within the TMJ⁽³⁸⁾. Surface-active phospholipid (SAPL) has an essential role in this mechanism, it serves to reduce wear and the friction of the articular surface⁽³⁹⁾. Under excessive joint loading the boundary mechanism adapts continuously by remodeling process, as a result of this process a phospholipase-A2 (PLA2) will be produced into the synovial fluid⁽⁴⁰⁾ it is responsible about lysis surface-active phospholipids. Ntiza *et al.*⁽³⁷⁾ clarify the role of HA in protection the surface-active phospholipids by inhibit action of phospholipaseA2.

Mouth opening

In this study, mouth opening was measured at 1st presentation, one and two months following PRP

therapy. There is a remarkable increase in the mouth opening of patients treated with PRP intr-articular injection one and two months after the treatment.

This observation is in line with a study conducted by Lippross *et al.*⁽⁴¹⁾ who found that PRP therapy reduces the level of all markers of inflammation and may help to maintain the integrity of the chondral surface and thereby facilitates the joint movement.

Since normal TMJ movement is mainly depending on the disc freely sliding down over the articular surface of the condyle and the slope of the eminence, which is covered with articular cartilage⁽⁴²⁾. Chondrocytes are the only cells that found in the articular cartilage, producing and maintaining the cartilage matrix⁽⁴³⁾. This matrix is mainly collagen and protglycan which is important to reduce the friction, with consideration of the lubrication system so any aberrations in this system may contribute in TMJ dysfunction⁽⁴²⁾. This observation is more likely reflective of the transforming growth factor (TGF-b) function, which is one of the most important factor involved in the process of cartilage regeneration including the increase in chondrocyte proliferation and matrix molecules production⁽⁴⁴⁾.

According to several previous studies, PRP promoted chondrocyte proliferation rate and may inhibit chondrogenic markers expression^(45; 46; 47; 48). This may support the current study findings of mouth opening improvement. Also, PRP can stimulate an increase in matrix molecule production which play a significant role in maintaining cartilage homoeostasis. This is consistent with a study conducted by Akeda *et al.*⁽⁴⁹⁾ who documented that PRP treatment may lead to higher amount of matrix.

Synovial fluid through its component of hyaluronic acid and lubricin is responsible for lubrication of the TMJ⁽³⁴⁾. It protects the articular cartilage from the erosion and protein deposition⁽⁵⁰⁾. PPR injection therapy may stimulate synoviocytes and increase the production of the hyaluronic acid⁽³⁷⁾.

Considering PRP preparation, previous study done by Slichter and Harker⁽⁵¹⁾ showed that double centrifugation method 1000×g for 9 minutes for the first step and 3000×g for 20 minutes for the second step resulted with decrease in platelets viability.

Other study performed by Dugrillon *et al.*⁽⁵²⁾ showed that PRP quality is more essential than platelet concentration and the number of platelet is

not always related to the GFs quantity. They also reported that transforming growth factor and platelet concentration is proportionally related to the force of centrifugation.

Mazzocca *et al.* (2012) studied three protocols for PRP preparation; the first one used a single spin at $180\times g$ (1500 rpm) for 5 min resulting with a low platelets and WBCs concentration. The second protocol was also single spin at $540\times g$ (3200 rpm) for 15 min, resulting with a high concentration of both platelets and WBCs. The third protocol was done using double step of centrifugation $180\times g$ (1500 rpm) for 5 min and 6300 rpm for 20 min, this produced a high concentration of platelets with lower WBCs. They proved that platelet concentration in second protocol was significantly higher than the other procedures.

According to Marx⁽⁵³⁾, the therapeutic level of platelet concentration in PRP preparation must be 1,000,000/ mL.

In the current study, PRP injection was prepared according to Mazzocca protocol which include 15 min centrifugation at $540\times g$ (3200 rpm). This protocol has been used due to the high concentrated number of platelets which full the criterion of the therapeutic application. This study is also agree with the study of Dugrillon *et al.*⁽⁵²⁾ who found that the centrifugal force must be less than $800\times g$ to preserve the platelet viability, taking in consideration the shorter period of time in preparation to prevent changes in platelet morphology and degranulation of growth factors⁽⁵⁴⁾. So, the reason behind choosing a single and short time for centrifugation is to have a better quality rather than better quantity of platelets in preparation of PRP therapy injection.

Kon *et al.*⁽⁵⁵⁾ used two different PRP preparation, high concentrated number of platelet with WBCs versus high concentrated number of platelet and low number of WBCs. To compare between their effect on 144 patients, who were evaluated up to 12 months; comparable results were obtained with both groups, with the only difference that PRP leukocyte group suffered from more swelling and sever pain reaction after the injection immediately. In the current study, no complications were recorded after the PRP injection immediately. Thus, it is different from the fore mentioned study.

Conclusion:

This study support the useful therapeutic effect of PRP as an intra-articular injection in the treatment of patients with ADDCWR. It has the ability to

improve functional outcome by reducing pain, clicking and increase range of mouth opening.

References:

1. Scully, Crispian *Oral and maxillofacial medicine: the basis of diagnosis and treatment* (2nd Ed.). Edinburgh: Churchill Livingstone 2008.
2. Sommer OJ. Cross –Sectional and functional imaging of the Tempromandibular joint: Radiology, pathology, and basic biomechanics of the jaw .Radio Graphic online 2003; 23, 14.
3. Nardini CI, Stifano M, Brombin C, Salmmaso L, Manfredini D. A one year series of arthrocentesis with hyaluronic acid injection fot TMJ osteoarthritis Oral surgery Med. Oral Pathol. Oral Radio. Endo, 2007; 103, 14-22.
4. Marx Platelet RICH Plasma: Evidance to Support Its Use. J Oral Maxillofac Surg 2004; 62:489-496.
5. Anitua E, Andia I, Ardanza B, Nurden P, Nurden AT. Autologous platelets as a source of proteins for healing and tissue regeneration. Thromb Haemost 2004; 91, 4- 15.
6. Anitua E, Sánchez M, Orive G. Potential of endogenous regenerative technology for in situ regenerative medicine. Adv Drug Deliv Rev 2010; (15) 62,741–752.
7. Mazzocca AD, McCarthy MB, Chowanec DM, Cote MP, Romeo AA, Bradley JP, et al. Platelet-rich plasma differs according to preparation method and human variability. J Bone Joint Surg Am 2012; 94,308–16.
8. Cie´slik-Bielecka A., T. Bielecki, T. S. Ga´zdzik, and T. Cie´slik, Growth factors in the platelet-rich plasma as autogenic material which stimulates bone healing processes, *Polish Journal of Stomatology*, 2006; 59, 7, 510–517.
9. Kostrzewa-Janicka J., Anulewiz A., and Mierzwinska-Nastalska E. Macroscopic and microscopic morphological aspects of temporomandibular joint overview, *Dental prosthodontics* 2007; 57(2), 97-104.
10. Di Matteo B., Filardo G., Lo Presti M., Kon, and Marcacci M. Chronic anti-platelet therapy: a contraindication for Platelet Rich Plasma intra-articular injection. *Europen Review for Medical and Pharmacological Sciences* 2014; 18(1), 55-59.
11. Senzel L, Gnatenko DV, Bahou WF. The platelet proteome. *Curr Opin Hematol* 2009; 5,329–333.
12. Sánchez M, Anitua E, Azofra J, Aguirre JJ, Andia I Intra-articular injection of an autologous preparation rich in growth factors for the treatment of knee OA: a retrospective cohort study. *Clin Exp Rheumatol*, 2008; 26, 910-913.
13. Nomura K, Vitti M, Oliveira AMS, Chaves TC, Semprini M, Siéssere S, et al. Use of the Fonseca's questionnaire to assess the prevalence and severity of temporomandibular disorders in Brazilian dental undergraduates. *Braz Dent J* 2007; 18,163-167.
14. Barros V de M, Seraidarian PI, Côrtes MI, de Paula LV. The impact of orofacial pain on the quality of life

- of patients with temporomandibular disorder. *J Orofac Pain* 2009; 23, 28-37.
15. Cortese SG, Fridman DE, Farah CL, Bielsa F, Grinberg J, Biondi AM. Frequency of oral habits, dysfunctions, and personality traits in bruxing and nonbruxing children: a comparative study. *J Craniomand Pract*, 2013; 31,283-290.
 16. Marcelo Oliveira Mazzetto, Carolina Almeida Rodrigues, Lais Valencise Magri, Melissa Oliverira Melchior, Guiovaldo Paiva. Department of Restorative Dentistry, Ribeirão Preto School of Dentistry, USP - University of São Paulo, Ribeirão Preto, SP, Brazil. Severity of TMD Related to Age, Sex and Electromyographic Analysis 2014; 25(1), 103-6440.
 17. Slade GD, Bair E, Greenspan JD, Dubner R, Fillingim RB, Diatchenko L, Maixner W, Knott C, Ohrbach R. Signs and symptoms of first-onset TMD and sociodemographic predictors of its development: the OPFERA prospective cohort study. *J Pain*, 2013; 14:20-32.
 18. Velly AM, Gornitsky M, Philippe P. Contributing factors to chronic myofascial pain: a case-control study. *Pain* 2003; 104,491-499.
 19. Steven *et al.* functional estrogen receptors increase the excitability of temporomandibular joint inflammation. 2014; 25(1), 103-6440.
 20. Flake NM, Bonebreak DB, Gold MS. Estrogen and inflammation increase the excitability of rat temporomandibular joint afferent neurons. *JNeurophysiol*, 2005; 93, 1585-1597.
 21. Hanci M, Karamese M, Tosun Z, Aktan TM, Duman S, Savaci N. Intra-articular platelet-rich plasma injection for the treatment of temporomandibular disorders and a comparison with arthrocentesis. *J Craniomaxillofac Surg*, 2015; 43(1), 162-6.
 22. Sánchez M, Anitua E, Azofra J, Aguirre JJ, Andia I. Intra-articular injection of an autologous preparation rich in growth factors for the treatment of knee OA: a retrospective cohort study. *Clin Exp Rheumatol*, 2008; 26,910-913.
 23. Sampson S, Reed M, Silvers H, Meng M, Mandelbaum B. Injection of platelet-rich plasma in patients with primary and secondary knee osteoarthritis: a pilot study. *Am J Phys Med Rehabil*, 2010; 89,961-969.
 24. Filardo G, Vannini F, Marcacci M, Andriolo L, Ferruzzi A, Giannini S, Kon E. Matrix-assisted autologous chondrocyte transplantation for cartilage regeneration in osteoarthritic knees: results and failures at midterm follow-up. *Am J Sports Med*, 2013; 41(1), 95-100.
 25. Kon E, Filardo G, Di Martino A, Marcacci M. Platelet-rich plasma (PRP) to treat sports injuries: evidence to support its use. *Knee Surg Sports Traumatol Arthrosc*, 2011; 19(4), 516-527.
 26. Napolitano M, Matera S, Bossio M, Crescibene A, Costabile E, et al. Autologous platelet gel for tissue regeneration in degenerative disorders of the knee. *Blood Transfus* 2012; 10, 72-77.
 27. Lee HR, Park KM, Joung YK, Park KD, Do SH. Platelet-rich plasma loaded hydrogel scaffold enhances chondrogenic differentiation and maturation with up-regulation of CB1 and CB2. *J Control Release*, 2012; 159(3), 332-337.
 28. Nishimura M, Segami N, Kaneyama K, Sato J, Fujimura K. Comparison of cytokine level in synovial fluid between successful and unsuccessful cases in arthrocentesis of the temporomandibular joint. *Journal of Oral and Maxillofacial Surgery* 2004; 62(3), 284-287.
 29. Woodell-May J, Pietrzak W. Platelet-rich plasma in orthopaedics. In: Pietrzak W (ed.), *musculoskeletal tissue regeneration*. Totowa, NJ: Humana Press 2008; 547-568.
 30. Pietrzak WS, Eppley BL. Platelet rich plasma: biology and new technology. *J Craniofac Surg* 2005; 16, 1043-1054.
 31. Woodall Jr J, Tucci M, Mishra A, Asfour A, Benghuzzi H Cellular effects of platelet rich plasma interleukin1 release from PRP treated macrophages. *Biomed Sci Instrum* 2008; 44, 489e494.
 32. Taylor DW, Petrera M, Hendry M, Theodoropoulos JS. A systematic review of the use of platelet-rich plasma in sports medicine as a new treatment for tendon and ligament injuries. *Clin J Sport Med*, 2011; 21(4), 344-352.
 33. Anitua E, Sanchez M, Nurden AT, Zalduendo MM, de la Fuente M, Azofra J, Andia I. Platelet-released growth factors enhance the secretion of hyaluronic acid and induce hepatocyte growth factor production by synovial fibroblast from arthritic patients *Rheumatology (Oxford)*. 2007; 46(12)1769-1772.
 34. Kure-Hattori I, Watari I, Takei M, Ishida Y, Yonemitsu I, et al. Effect of functional shift of the mandible on lubrication of the temporomandibular joint. *Arch Oral Biol* 2012; 57,987-994.
 35. Laurent TC, Laurent UBG, Fraser JRE. The structure and function of hyaluronan: an overview. *Immunol Cell Biol* 1996; 74, 1-7.
 36. Mow VC, Ateshian GA. Lubrication and wear of diarthrodial joints. In: Mow VC, Hayes WC, eds. *Basic orthopaedic biomechanics*, edn 2. Philadelphia, PA: Lippincott-Raven 1997; 275-315.
 37. Nitzan DW, Dan P, Yedgar S. the role of hyaluronic acid in protecting surface-active phospholipids from lysis by exogenous phospholipase A2. *Rheumatology (Oxford) J Oral Medicine*, (2001); 40(3)336-340.
 38. Schmidt, T. A., and R. L. Sah. Effect of synovial fluid on boundary lubrication of articular cartilage. *Osteoarthritis Cartilage* 2007; 15, 35-47.
 39. Higaki H, Murakami T, Nakanishi Y *et al.* The lubricating ability of biomembrane models with dipalmitol phosphatidylcholine and gamma-globulin. *Eng Med* 1998; 21,337-46.
 40. Vadas P, Browning J, Edelson J *et al.* Extracellular phospholipase A₂ expression and inflammation: the relationship with associated disease states. *J Lipid Mediators* 1993; 8, 1-30.
 41. Lippross S, Moeller B, Haas H, Tohidenezhad M, Steubesand N, Wruck C *et al.* Intra-articular injection of platelet-rich plasma reduces inflammation in a pig model of reumatoid arthritides of the knee joint. *Arthritides Rheum*, 2011; 63(11): 3344-3353.

42. Hegab, A. Temporomandibular Joint Internal Derangement. Dent Health Oral Disord Ther 2015; 2(1), 00033.
43. Lee HR, Park KM, Joung YK, Park KD, Do SH. Platelet-rich plasma loaded hydrogel scaffold enhances chondrogenic differentiation and maturation with up-regulation of CB1 and CB2. J Control Release 2012; 159(3), 332–337.
44. Filardo G, Vannini F, Marcacci M, Andriolo L, Ferruzzi A, Giannini S, Kon E. Matrix-assisted autologous chondrocyte transplantation for cartilage regeneration in osteoarthritic knees: results and failures at midterm follow-up. Am J Sports Med 2013; 41(1), 95–100.
45. Yang SY, Ahn ST, Rhie JW, Lee KY, Choi JH, Lee BJ, Oh GT. Platelet supernatant promotes proliferation of auricular chondrocytes and formation of chondrocyte mass. Ann Plast Surg 2000; 44(4), 405–411.
46. Kaps C, Loch A, Haisch A, Smolian H, Burmester GR, Häupl T, Sittinger M. Human platelet supernatant promotes proliferation but not differentiation of articular chondrocytes. Med Biol Eng Comput 2002; 40(4), 485–490.
47. Gaissmaier C, Fritz J, Krackhardt T, Flesch I, Aicher WK, Ashammakhi N. Effect of human platelet supernatant on proliferation and matrix synthesis of human articular chondrocytes in monolayer and three-dimensional alginate cultures. Biomaterials 2005; 26(14), 1953–1960.
48. Drengk A, Zapf A, Stürmer EK, Stürmer KM, Frosch KH. Influence of platelet-rich plasma on chondrogenic differentiation and proliferation of chondrocytes and mesenchymal stem cells. Cells Tissues Organs 2009; 189(5), 317–326.
49. Akeda K, An HS, Okuma M, Attawia M, Miyamoto K, Thonar EJ, Lenz ME, Sah RL, Masuda K. Platelet-rich plasma stimulates porcine articular chondrocyte proliferation and matrix biosynthesis. Osteoarthritis Cartil 2006; 14(12), 1272–1280.
50. Rhee DK, Marcelino J, Baker M, Gong Y, Smits P, et al. The secreted glycoprotein lubricin protects cartilage surfaces and inhibits synovial cell overgrowth. J Clin Invest 2005; 115, 622–631.
51. Slichter SJ, Harker LA. Preparation and storage of platelet concentrates. I. Factors influencing the harvest of viable platelets from whole blood. Br J Haematol 1976; 34, 395–402.
52. Dugrillon A, Eichler H, Kern S, Klüter H. Autologous concentrated platelet-rich plasma (cPRP) for local application in bone regeneration. Int J Oral Maxillofac Surg 2002; 31, 615–9.
53. Marx RE: Platelet-rich plasma: evidence to support its use. J Oral Maxillofac Surg, 2004; 62, 498-93.
54. Nagata MJ, Messori MR, Furlaneto FA, et al. Effectiveness of two methods for preparation of autologous platelet-rich plasma: an experimental study in rabbits. Eur J Dent 2010; 4, 395-402.
55. Kon E, Mandelbaum B, Buda R, Filardo G, Delcogliano M, Timoncini A, Fornasari PM, Giannini S, Marcacci M. Platelet-rich plasma intra-articular injection versus hyaluronic acid viscosupplementation as treatments for cartilage pathology: from early degeneration to osteoarthritis. Arthroscopy 2011; 27, 1490–1501.

فعالية حقن البلازما الغنية بالصفائح الدموية داخل المفصل الفكي الصدغي في المرضى الذين يعانون من نزوح القرص الى الامام مع الرجوع

الخلاصة

خلفية: حركة القرص الى الامام مع الرجوع هو من اكثر الاضطرابات الداخلية شيوعا للمفصل الفكي الصدغي. وهو خلل تدريجي في وظيفة المفصل يتميز سريريا بالم في المفصل واصوات فرقعة مفصلية بسبب حركة القرص فيما يتعلق باللحمة والحفرة خلال غلق الفك السفلي. يمكن ان تستخدم تقنية العلاج المعتدلة، ولكن اذا كانت غير فعالة يمكن استخدام الحقن بمادة البلازما الغنية بالصفائح الدموية داخل المفصل والتي تعتبر طريقة اقل من التداخل الجراحي. البلازما الغنية بالصفائح الدموية هو نتاج ذاتي طبيعي يتميز تركيز عالي من الصفائح الدموية التي يتم الحصول عليها بعملية الطرد المركزي لتعزيز شفاء الأنسجة موضعيا من خلال مجموعة من عوامل النمو الموجودة في حبيبات الفا. وتطلق هذه العوامل عبر عملية التحبيب بعد تفعيل الذاتي. وتستخدم هذه التقنية اليوم بشكل متزايد باعتبارها طريقة بسيطة وامنة.

الهدف من الدراسة: لتقييم فعالية الحقن بمادة البلازما الغنية بالصفائح الدموية داخل المفصل الفكي الصدغي للمرضى الذين يعانون من حركة القرص الى الامام مع الرجوع.

المواد وطرائق العمل: شملت الدراسة مشاركة 60 مريض كانوا يعانون من حركة القرص الى الامام مع الرجوع، 41 من الاناث و 19 من الذكور تتراوح اعمارهم بين (20-30) سنة. تم تقسيمهم الى مجموعتين الاولى المكونة من 30 مريض والذي سبق ان تم علاجهم بالتقنيات المعتدلة بدون اي استجابة فتم حقنهم بالصفائح الدموية الغنية بالبلازما والذي تم اعتبارهم مجموعة الدراسة اما المجموعة الثانية فتتكون ايضا من 30 مريض وتم علاجهم بالتقنيات المعتدلة وتم اعتبارهم المجموعة الضابطة اما طريقة العمل المستخدمة للحقن داخل المفصل كانت تتضمن جمع 10 مل من الدم الوريدي للمريض كعينة ، 1 مل من تركيز البلازما الغنية من الصفائح الدموية تم الحصول عليه بواسطة خطوة واحدة للطرد المركزي. تم تقييم الام ، فتحة الفم القصى من دون مساعدة بالاضافة الى اصوات الفرقعة في المفصل الفكي الصدغي سريريا قبل وبعد الشهر الاول والثاني من العلاج.

النتائج: هناك تحسن ثابت في الحد من درجة الألم وأصوات النقر المتبادل و زيادة كبيرة في فتحة الفم . مع عدم وجود أي مضاعفات بعد الحقن مباشرة و عند المتابعة.

الاستنتاجات: هذه الدراسة تدعم فعالية حقن البلازما الغنية بالصفائح الدموية داخل المفصل الفكي الصدغي لعلاج اضطرابات حركة القرص الى الامام مع الرجوع كونه طريقة امنة لتقليل الالم واصوات الفرقة المفصليية وزيادة فتحة الفم والتي بالتالي تحسن وظيفة المفصل.