

Evaluation of effect of local exogenous application of Myrrh oil on healing of wound incisions of facial skin (Histochemical, Histological and Histomorphometrical study in rabbits)

Nawar Bahjet Kamil, B.D.S, M.Sc. ⁽¹⁾

Nada M. H. Al-Ghaban, B.D.S, M.Sc., Ph.D. ⁽¹⁾

Abstract

Aim of the study: Is to evaluate the effect of myrrh oil local application on the healing process of skin wounds histologically, histomorphometrically and, histochemically.

Materials and methods: Twenty male white New Zealand rabbits were used in this study. An incisional wounds with full thickness depth and of 2 cm length were done on both sides of the cheek skin of each rabbit. The left sided incisions (the control group) were irrigated with distilled water (10µL). The right sided incisions (the experimental groups) were treated with myrrh oil (10µL). Each group was subdivided into 4 subgroups according to the healing interval into 1,3,7 and 14 days (5 rabbits for each group).

Results: Histological findings of our current study showed a highly significant difference between the experimental and the control groups in count of the inflammatory cells which showed that mean values increased with time for the control and the experimental groups. The histomorphometrical findings had shown that the thickness of the epithelium was nearly completed at about 7 days for the experimental groups and at about 14 days for the control. The blood vessels count was recorded to have a highly significant difference between the groups at days 1 and 3 only. The histochemical findings had shown that the collagen fibers remodeling had recorded a highly significant difference between the control and the experimental groups at days 7 and 14.

Conclusion: The current study had revealed that myrrh oil accelerates wounds healing in rabbits.

Key word: Wound healing, Myrrh oil, Masson's Trichrome staining. (Received: 25/11/2018; Accepted: 3/1/2019)

INTRODUCTION:

The skin can be defined as an interface or a barrier between the body and the external environment ⁽¹⁾. A wound can be described as a loss of the function and integrity of the body tissues. The injury can be usually caused by an external force (traumatic/accidental or surgical) and it can involve any type of organs or tissues ⁽²⁾.

The process of wound healing, which is considered a normal biological process of the body, can be achieved by four highly programmed, strict and precise phases. These phases include: "hemostasis, inflammation, proliferation, and remodeling". For a successful healing of any wound, the four phases must occur in the proper sequences and accepted time limit ⁽³⁾.

Myrrh oil is described as a hardened sap that oozes from the *Commiphora molmol* stem (Family Burseracea) tree. It is collected from the natural cracks or it can be from cuts made by human in the trees bark ⁽⁴⁾. Myrrh had been used frequently in the recorded history and it had been considered to be a fragrance and also a medical agent by "the ancient Chines and by the old Egyptians" ⁽⁵⁾. "Caryophyllene C₁₅H₂₄" which is present in myrrh oil also has an anti inflammatory, antibacterial and anti tumor action ⁽⁶⁾.

1. Department of Oral Diagnosis, College of Dentistry, University of Baghdad.

MATERIALS AND METHODS

Twenty New Zealand male rabbits, of (1.5– 2 kg) body weight and (4-7) months of age were used in this study. All of the rabbits were housed with controlled ventilation conditions and temperature and were given a standard diet (barseem and pellet) with an easy accessed tap water. The animals were kept in a standard separated cages for 2 weeks in the same suitable environment before the surgical procedure.

All of the animals underwent examination by "veterinarian staff in the animal house of Biotechnical Research Center at Alnahrain Unniversity" for the evaluation of their general condition and health in order to exclude any unhealthy animals. The animals then were fasted about 6-8 hours before the operation. All of the experimental procedures were done in accordance with "the animal experimentation ethical principles" ⁽⁷⁾.

A full skin thickness surgical incisional wounds and 2 cm length were done on both sides of the cheek skin for each rabbit ⁽¹¹⁾. The animals then were randomly divided in accordance to the healing intervals into 4 groups (1,3,7,14) (5 rabbits in each group) and each group was subdivided in to: 1- Control group: The left sided incisions were irrigated with distilled water.

2- Experimental group: The right sided incisions

were treated with 10µL of a myrrh oil. All of the specimens were taken and prepared for the histological (H&E stain) and the histochemical examination with masson's trichrome stain for collagen fibers density assessment.

Assessment of wound healing parameters

clinical assessment

- Wound contraction:

At 3,7 and 14 days period interval the wounds were measured by ruler (8,9).

2 Histological analysis

1. Inflammatory cells analysis :

With power x40 lens, we counted the inflammatory cells number in five fields and then recorded the mean number of cells (10).

2. Epithelial thickness assessment:

With power x40 lens, the measurement of the epithelial thickness was performed by measuring the distance from the outermost layer of the epidermal keratin to the inner most basal layer of it at the edges of the wound as a mean of two readings with the help of Image J computer software (11).

3. Blood vessels analysis:

Blood vessels analysis was done using the Image J software. Using light microscope, power x40 lens (12).

4. Collagen fiber density analysis:

The slides were stained with masson's trichrome stain and were examined under the light microscope, power x40, at 3,7 and 14 days period intervals with the help of image J software (13).

RESULTS

wound contraction estimation:

Table (1) is showing that with time there is a decrease in the recorded mean values, and that there is a high significant difference between the control and the experimental groups in all healing periods.

Inflammatory cell parameter

The results showed as in table (2) that the highest mean values were recorded for the experimental groups at day 3 and the lowest mean value was at 14 days.

The epithelial thickness parameter: results had revealed as shown in table (3) that the epithelial thickness highest mean value for the control and the experimental groups was recorded at day 14 and that the lowest mean value for both both groups was recorded at day 1, also it showed a highly significant differences between the control and the experimental groups at all healing period intervals (p<0.01).

Table 1: Descriptive statistics of wound contraction at different healing period

Time/day	Control Mean±SD	Myrrh Mean ±SD	P value	LS D
3 Days	1.86	1.56	0.000* *	0.30
7 Days	1.50	1.18	0.000* *	0.32
14 Days	0.80	0.09	0.000* *	0.71

Table 2: Descriptive statistics of inflammatory cells account in each period interval

Time/day	Control Mean±SD	Myrrh Mean±SD	pvalue	LSD
1 days	0.95	1.9	0.000**	-4.8
3days	3.81	7.94	0.000**	-20.5
7days	17.69	32.41	0.000**	-6.82
14days	42.11	63.22	0.000**	-18.84

Blood vessels account:

As shown in table(4), the study revealed that the blood vessels count highest mean value that was

recorded for the experimental groups was at day 3, and for the control groups was at day 7. While the control and experimental groups lowest mean

values were recorded at day 1 and there was no significant difference at 7 and 14 days.

Collagen fiber density:

The study results revealed that the recorded highest mean values for the control and the

experimental groups were at 14 days and the lowest mean values were recorded at day 3 as shown in table 5.

Histological finding (H&E and Masson’s Trichrome chemical stain)

- **One day duration: (Control group) Fig. (1)**

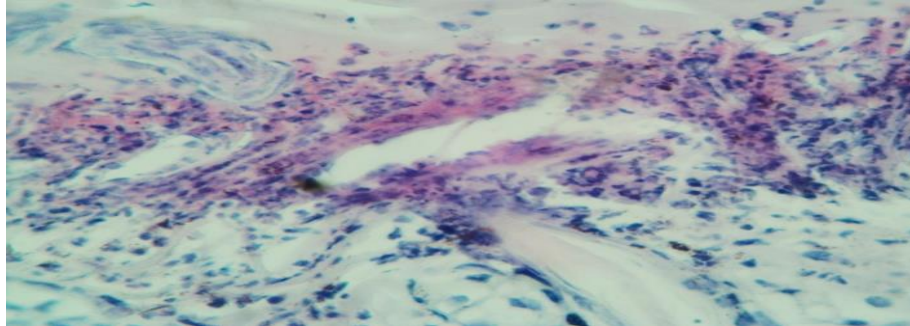


Fig. 1: View of control group at day 1 showed inflammatory cells infiltration and scab, H&E, X40.

One day duration :Experimental group (M) Fig. (2)

Table 3: Descriptive statistics of epithelial thickness (µm) in each period interval

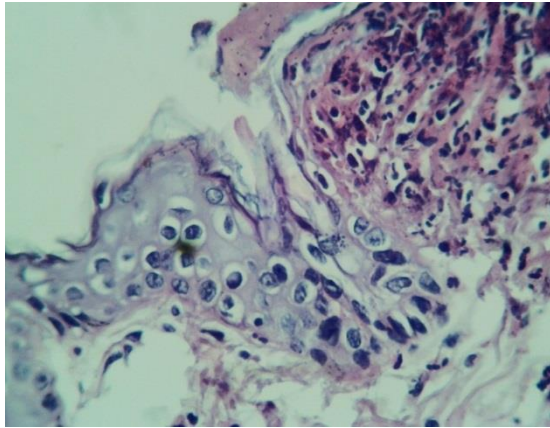
Time/day	Control Mean±SD	Myrrh Mean±SD	P value	LSD
1 Day	0.80	2.40	0.003**	-1.40
3 Days	3.60	7.40	0.000**	-4.60
7 Days	7.80	5.80	0.09	1.00
14 Days	6.40	5.90	0.52	0.40

Table 4: Descriptive statistics of blood vessels account in each period interval

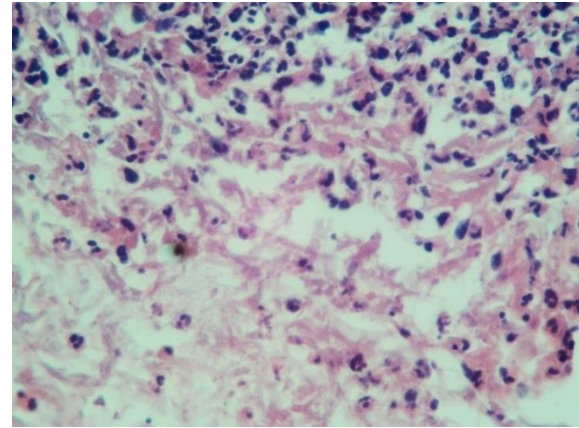
Time/day	Control Mean±SD	Myrrh Mean±SD	P value	LSD
3days	18.83	41.43	0.000**	-22.6
7days	24.19	54.72	0.000**	-29.4
14days	44.11	68.67	0.000**	23.5

Table (5) Descriptive statistics of the collagen fiber density (%) in each period interval

Time/day	Control Mean±SD	Myrrh Mean±SD	P value	LSD
1 Day	11.80	31.40	0.000**	-19.6
3 Days	17.60	27.00	0.000**	-9.4
7 Days	26.40	15.20	0.000**	9.2
14 Days	22.80	10.60	0.000**	12.2



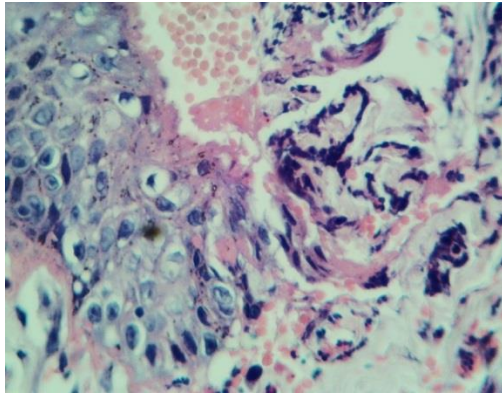
A



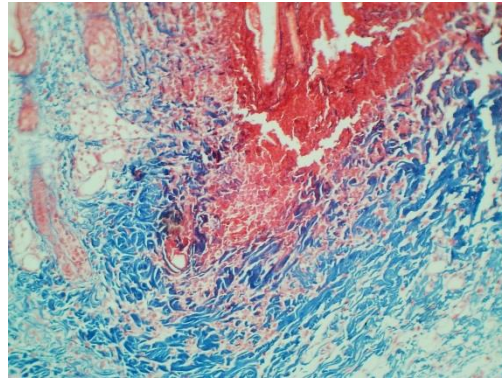
B

Figure 2: View of Myrrh oil group at day 1 showed A: Epithelial cutting edge and migration of basal cell , H&E,X40.B: showed infiltration of Inflammatory cells in dermis as black points,H&E,X40.

Three days duration(Control group) Fig. (3).



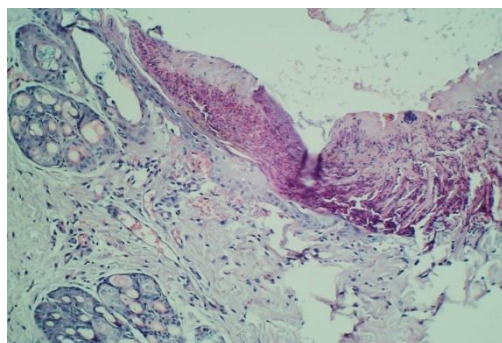
A



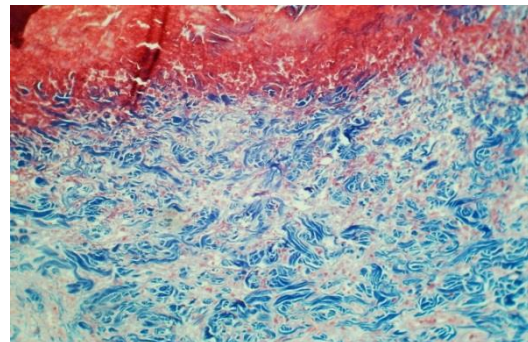
B

Figure 3: View of control group at day 3 showed showed A: epithelial proliferation, H&E, X40 B: Fine collagen fiber and granulation tissue MTX10.

Three days duration Experimental group(M) Fig. 4.



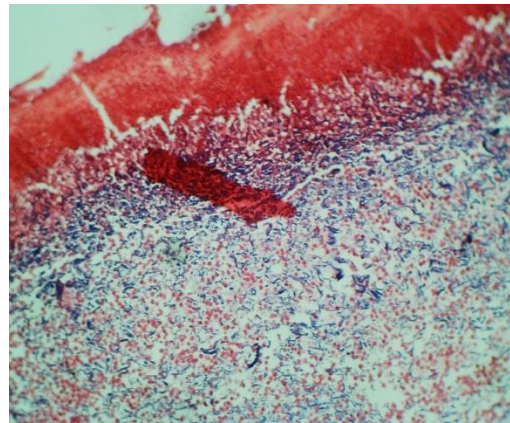
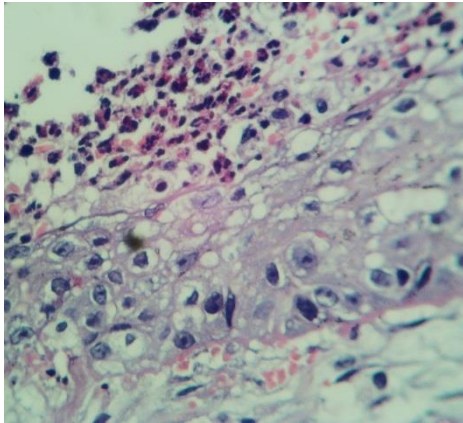
A



B

Figure 4: View of Myrrh oil at day 3 showed ,A: scab, new epithelium , infiltrationof inflammatory cells and hair follicle, H&E,X10.B: new fine collagen fiber, MT,X40.

Seven days duration(Control group) Fig. 5.

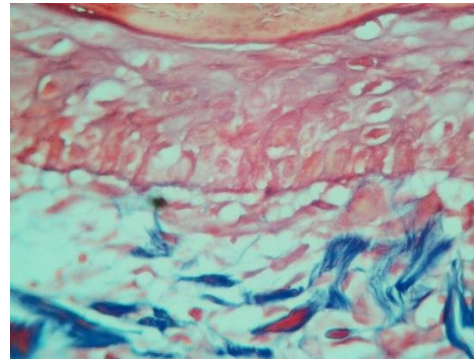
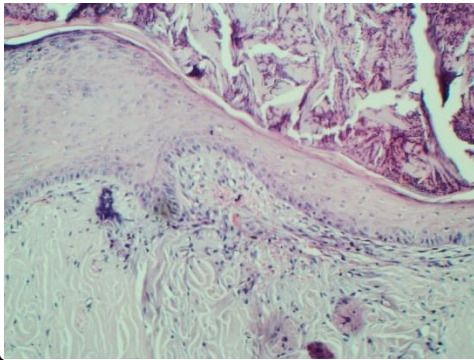


A

B

Figure 5: View of control group at day 7 showed, new epithelium formation, and scab, H&E,X10..B: G: granulation tissue, blue area: coarse of collagen fibers, MT, X40.

Seven days duration (Experimental group): Fig. 6

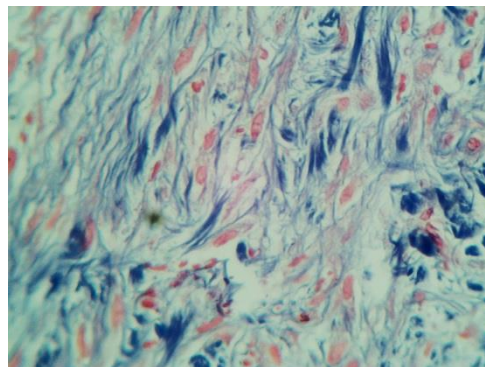
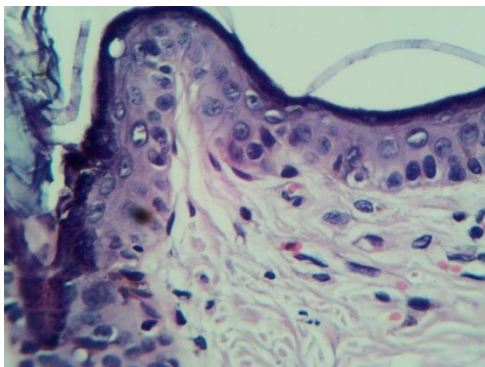


A

B

Figure 6: View of Myrrh oil group at day 7 showed, A: keratin , New epithelium, H&E,X10.B: blood vessels, Col: coarse of collagen fibers, G: granulation tissue, MT, X40.

Fourteen days duration: Control group: Fig. 7

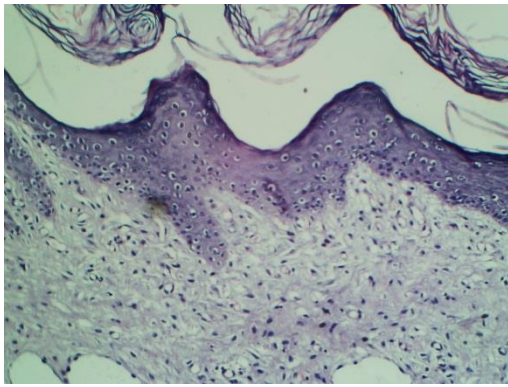


A

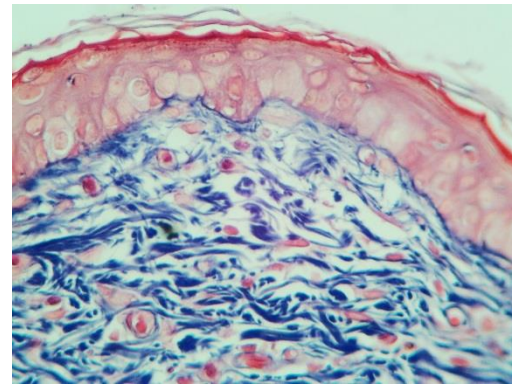
B

Figure 7: View of control group at day 14 showed, A: keratin layer, epidermis, granulation tissue, H&E,X10. B: granulation tissue and blue area: remodeling of collagen fiber. MT,X40.

Fourteen days duration (Experimental group):Fig. 8



A



B

Figure 8: View of Myrrh oil group at day 14 showed, A: keratin layer, HF, complete formation of epithelium, H&E, X10. B: large area occupied by remodeling collagen fiber (Col) and invaded by blood vessel, MT, X10.

DISCUSSION

Nowadays, medicinal herbals are considered to be one of the branches of the complementary and alternative medicine. Herbals use for caring of wounds and injuries had been known since the ancient civilizations^(14,15).

Our present study had shown that wounds contraction was accelerated in the experimental groups as compared to the control groups. This acceleration in the wounds contraction can be explained be due to the increased proliferation and progression of the epidermal cells in the experimental groups and because of the anti-inflammatory effect of this oil⁽¹⁶⁾.

Histological and histomorphometrical evaluation: In our study the experimental groups had displayed variable degrees of the inflammatory reaction especially in the first 24 hours, in contrast to the control groups which had displayed a more prolonged and sever inflammatory reaction extending up to the 7th day attributed to the bacterial colonization and the lack of the immunomodulation and the anti-inflammatory activities. This agrees with (Al-Mobeeriek,2011)⁽¹⁷⁾

The intensity of the inflammatory cells in the wounds areas was found to be predominant and the density of the inflammatory reactions was more sever in experimental groups as compared to the control groups in the 1st and 3rd day, while in the 7th and 14th days the inflammatory cells had become mild because of the established and completed inflammatory stage and the start of the remodeling stage in the experimental groups, while they recorded a high mean value in the control groups at day seven and a decrease in day fourteen. This may be because of the anti bacterial effects of the myrrh oil^(18,19) and this had led to

the promotion and the acceleration of the healing processes.

Neovascularization is another very important event that should take place in the 2nd stage of the wound healing⁽²⁰⁾. In our study, in the 1st day, the neovascularization in the control groups was found to be little or nearly absent, while in the experimental group, it was present but to a very little extent, High significant differences was recorded between the control groups and the experimental groups in day 1 and 3 but there was a none significant difference in the days 7 and 14. The early neovascularization in the experimental groups had led to promote the healing process because new vessels usually supplies oxygen and the required nutrients and remove the waste products⁽²¹⁾.

The present study had shown that the re-epithelialization had occurred faster in the experimental groups and it recorded a high significant difference as compared to the control groups because of the increased proliferation and the progression of the epidermal cells with an increment in the amount of the neovascularization, the fibroblast cells and the collagen fiber of the dermal layer in the experimental groups and this agrees with (Al-Mobeeriek,2011)⁽¹⁷⁾, The remodeling phase had started earlier in the experimental groups than in the control groups and this agrees with a previous study (Al-Mobeeriek,2011)⁽¹⁷⁾.

"Masson's trichrome stain" was used in this study for assessment of the density of the collagen fiber, this agrees with previous study (Suvik, and Effendy, 2012)⁽¹³⁾The experimental groups had been found to have a higher collagen density than the control groups at day 3,7 and 14 and this agrees with a previous study (Enoch and Leaper, 2007;Reinke and Sorg, 2012)^(22,23)

CONCLUSION

Myrrh oil has the ability to accelerate healing of the wounds because of the faster wounds contraction, early neovascularization, re-epithelization and a higher collagen density than the control groups. Myrrh oil groups had shown an anti-inflammatory effects which is identified by a decrease in the count of the inflammatory cells with time.

REFERENCES

1. Hongbo, Z. and Maibach, H.I. 2004. Dermatotoxicology. CRC Press LCC, USA, 6: 938-955.
2. Rose, L. and Hamm, D.P.T. 2015. text and atlas of wound diagnosis and treatment, New York McGraw Hill, chapter (1): 1-39.
3. Thiruvoth, F.M., Mohapatra, D.P., Kumar, D., Chittoria, S.R.K., Nandhagopal, V. 2015. Current concepts in the physiology of adult wound healing. plastic and esthetic research. India, 2: 250-6.
4. Marshall, S. 2004. Myrrh: Magi, medicine and mortality. The pharmaceutical J. 273: 919-921.
5. Etman, M., Amin, M., Nada, A.H., Shams-Eldin, M. and Salama, O. 2011. Emulsions and rectal formulations containing myrrh essential oil for better patient compliance. Drug Discov Ther, 5, 150 - 156.
6. Suad, A. Gadir, Ibtisam, M. and Ahmed, J. 2014. Chem. Pharm. Res., 6(7): 151-156.
7. Rollin, A. and Bernard, E. 2006. The regulation of animal research and the emergence of animal ethics: A conceptual history. Theoretical medicine and bioethics, 27(4): 285-304.
8. AL-Kadhimi, B., J. 2014. Effect of topical application of estrogen hormone on wounds healing in ovariectomized rabbits, university of Baghdad, M.Sc. thesis.
9. Kumar, A., Chomwal, R., Kumar, P. and Sawal, R. 2009. Anti inflammatory and wound healing activity of curcuma aromatic salisb extract and its formation. Journal of chemical and pharmaceutical research, 1(1): 304-310.
10. Accorinate, M., Holland, R., Reise, A., Bortuluzzi, M. and Murate, S. 2008. Union of mineral trioxide cement as pulp capping agent in teeth. Journal of endo, 34: 1-6.
11. Gal, P., Vidinsky, B. and Toporcer, T. 2006. Histological assessment of the effect of laser irradiation on skin wound healing in rats. Photomed. Las. Surg., 24(4): 408-488.
12. Wosgrau, ACC., Jeremias, Td., Leonardi, D.F., Pereima, M.J. Di., Giunta, G. and Trentin, AG. 2015. Comparative Experimental Study of Wound Healing in Mice: Pelnac versus Integra. PloS one journal, 10(3).
13. Suvik, A. and Effendy, A.W.M. 2012. The use of modified Masson's Trichrome staining in collagen evaluation wound healing study. Malaysian Journal of Veterinary Research 3 (1): 39-47.
14. Hajiaghaalipour, F., Kanthimathi, M.S., Abdulla, M.A. and Junedah Sanusi, J. 2013. The effect of Camellia sinesis on wound healing potential in an animal model. Evidence-based complementary and alternative medicine research article, 2: 1-7.
15. Nezhad, H.R., Sahrri, N.M. and Rakhshandeh. 2013. The importance of tomeric extract on wound repair in rats. Animals of biological research, 4(12): 123-128.
16. Shalaby, M.A. and Hammouda, A.A.E. 2014. Analgesic, anti-inflammatory and anti-hyperlipidemic activities of *Commiphora molmol* extract (Myrrh). J Intercult Ethnopharmacol, 3(2): 56-62.
17. Al-Mobeeriek, A. 2011. Effect of myrrh on intra oral mucosal wounds compared with tetracycline and chlorhexidine based mouth washes. Clinical, cosmetic and Investigational Dentistry, 3: 53-58.
18. Almekhlafi, S., Anes, A. M., Thabit, Ameen, M. I., Alwossabi, Awadth, N. Abdulbaqi, A. M. and Zaid Algaadari, Z. 2014. Antimicrobial activity of Yemeni myrrh mouthwash. Journal of Chemical and Pharmaceutical Research, 6(5): 1006-1013.
19. Elsarag, S.M.M. 2008. The activity of commiphora myrrh against microorganism recovered from wounds. msc thesis, Sudan University of Science and Technology.
20. Gurtner, G.C., Werner, S., Barrandon, Y., Longaker, M.T. Wound repair and regeneration. Nature. 2008; 453 (7193): 314-21.
21. Shaykhiev, R., Beisswenger, C. and Kandler, K. 2005. Human endogenous antibiotic LL-37 stimulates airway epithelial cell proliferation and wound closure. Am J Physiol Lung Cell Mol Physiol. 289(5): L842-848.
22. Enoch, S. and Leaper, D.J. 2007. Basic science of wound healing. Surgery; 26(2): 31-37.
23. Reinke, J.M. and Sorg, H. 2012. Wound repair and regeneration. Eur Surg Res., 49: 35-43.

الخلاصة

خلفية الموضوع: الجروح هي فقدان الوظيفة الحيوية وسلامة النسيج أو العضو يحدث بسبب تداخل جراحي أو حادث. التئام الجروح يعتبر عملية بيولوجية طبيعية في جسم الإنسان ويتحقق من خلال أربع مراحل مبرمجة بدقة عالية وهي: وقف النزف، التهاب، التكاثر وإعادة البناء. طب الاعشاب يمكن ان يعرف كواحد من فروع الطب بأشكال مختلفة، وقد أثبتت نبات المرة خصائصه كمضاد للالتهابات ومعقم للجروح والخدوش ومحفز لالتئام الجروح وعلاج الالتهابات. أهداف الدراسة: تقييم تأثير الاستخدام الموضعي لزيت المرة نسيجيًا، كمنسج كيميائي وتحليل شكلي نسيجي. المواد والطرائق: تم استخدام أربعين أرنبًا نيوزلنديًا في هذه الدراسة وتم عمل جرح كامل السمك وبطول سنتيمترين على جانبي جلد الخد الأيمن والأيسر، مجموعة التحكم (وتشمل عشرون جرح في الجهة اليمنى تم غسلهم بالماء المقطر)، مجموعة زيت المرة (وتشمل عشرون جرح وتم معالجتهم بعشرة ماكروميتر من زيت المرة) ثم قسمت إلى أربع مجاميع حسب فترة الشفاء (1, 3, 7, 14 يوم) كل العينات تم تحضيرها نسيجيًا باستخدام صبغة الهيماتوكسلين والإيوزين وتم تقييم الخلايا الالتهابية، سمك الطبقة الطلانية وعدد الاوعية الدموية، أيضا تم تحضير العينات باستخدام الصبغة الكيميائية ماسون ترائي كروم وتم فحص الاليف الكولاجينية. النتائج: النتائج النسيجية للدراسة الحالية اوضحت بان زيت المرة له القدرة على تسريع التئام الجرح حيث ان جميع مجاميع التجربة كانت لها اقل معدل قيمة في اليوم 14 بالمقارنة مع مجموعة التحكم. كما اثبتت ان زيت المرة لهما الخاصية المضادة للالتهابات حيث لوحظ ان عدد الخلايا الالتهابية قد تناقصت مع مرور الوقت.

دراسة النسيج الشكلي اوضحت ان سمك الخلايا الطلانية في مجموعة التجربة تقريبا اكتمل في اليوم السابع بينما مجموعة التحكم اكتمل سمك الخلايا الطلانية في اليوم 14.
تكوين الاوعية الدموية كان اسرع في مجاميع التجربة بالمقارنة مع مجموعة التحكم.
دراسة النسيج الكيميائي اوضحت ان الالياف الكولاجينية سجلت اختلاف عالي ومهم بين مجموعة التحكم ومجموعة التجربة في الايام (3،7،14)، وكان اكثر كثافة في مجاميع التجربة.