

Review Article

Efficacy of a single antimicrobial photodynamic therapy session as an adjunct to non-surgical periodontal therapy on clinical outcomes for periodontitis patients. A systematic review

Ahmed R Atarchi ^{1*}, Zaid R Atarchi ²

¹ Bright Now Dental Corporate, San Francisco, California, USA

² Oaklawn implant and dental center, 5821 W 87th street, Oaklawn, IL 60453, USA

* Corresponding author: ahmedatarchi77@gmail.com

Received date:11-07-2023

Accepted date:15-08-2023

Published date:15-09-2023



Copyright: © 2022 by the authors. Submitted for possible open access publication under the terms and conditions of the Creative Commons Attribution (CC BY) license (<https://creativecommons.org/licenses/by/4.0/>).
<https://doi.org/10.26477/jbcd.v35i3.3497>

Abstract: Background: periodontitis is a multifactorial and multi-etiological disease associated with destructive events to the periodontium. Non-surgical periodontal therapy (NSPT) is considered an efficient, gold-standard approach to treat this disease; however, several variables could hinder the success rate. Combining antimicrobial photodynamic therapy (aPDT) with NSPT showed promising results but the available literature show variations in results. Aim: whether using single episode of aPDT as adjunct to NSPT for adults affected by periodontitis can improve clinical outcomes, with a minimum 3 months follow up after terminating active treatment, as compared to conventional manual instrumentation? Methods: Three databases (PubMed, ScienceDirect, and Cochrane Library) were searched to retrieve relevant articles. The keywords matrix used for the search process consisted of the following terms: periodontitis OR periodontal disease AND photodynamic therapy OR antimicrobial photodynamic therapy OR Laser. Results: A total of 4104 articles were retrieved from the search process for the last 10 years. After removing duplicates and applying filters, 44 article were eligible for full-text reading. The last step resulted in 6 randomized controlled trials that were used for data synthesis. Conclusions: Retrieved data from this study indicated that adjunctive aPDT has a potential beneficial effect on short-term mainly reflected by improving bleeding scores and microbiological outcomes for patients with periodontitis. However, longer term advantage was not evident as compared to conventional periodontal therapy. Further studies are advised to draw a solid conclusion about using aPDT as adjunct to NSPT

Keywords: Periodontitis; photodynamic therapy; non-surgical periodontal therapy; photosensitizer; randomized clinical trials.

Introduction

Periodontitis is a multi-etiological disease with destructive consequences on the oral health; however, certain pathogenic bacteria is considered as the main factor that drives the dysbiosis of the symbiotic microbiota ⁽¹⁾. Consequently, inflammation-associated damage of supporting periodontal tissues initiated ending with loss of teeth at advanced stages of the disease ⁽²⁾. The main target of periodontal therapy is to mechanically disrupting and eradicating pathogenic dental biofilm to restore the healthy state of periodontium ⁽³⁾. Over decades, the conventional periodontal therapy has constantly reviewed and proved to be efficacious in treating periodontitis with different severities ⁽⁴⁾. Nevertheless, unfavorable response is expected in certain cases due to failure to eliminate periodontal pathogens particularly in molar teeth with furcation involvement ^(4,5). The odds of residual pockets presence after non-surgical periodontal therapy (NSPT) are increased with deep pocket where incomplete elimination of the dysbiotic biofilm and calculus is highly expected ⁽⁶⁾. Several adjuncts were proposed to improve the clinical outcomes of scaling and root planing (SRP) such as local application of antibiotics, antiseptics, antioxidants, and photosensitizer-mediated

therapy⁽⁷⁻⁹⁾. However, till now, there no consensus about which is the best adjunctive therapy that could significantly improve the outcomes of NSPT.

Antimicrobial photodynamic therapy (aPDT) is a type of medical therapy that involves exciting of the photosensitizer, in the presence of oxygen, by application of light with a specific wavelength⁽¹⁰⁾. This reaction is considered cytotoxic which resulted in production of oxygen species such as free radicals and singlet oxygen leading to cellular damage and death. This mechanism minimizes the chance of developing bacterial resistance since the products of this reaction can affect multiple cellular elements⁽¹¹⁾ which suggested aPDT as a useful alternative to antibiotics. Additionally, the commercially available photosensitizers such as Indocyanine green (ICG), Methylene blue and Toluidine blue are commonly used in the medical field and considered safe when administrated via intravenous injection, orally, and topically applied^(12,13).

PDT has been introduced in the contemporary dental practice for treating wide range of oral diseases/conditions including cancers, autoimmune, viral, bacterial, and fungal infections⁽¹⁴⁾. Additionally, the use of PDT as adjunctive to periodontal therapy has gained interest, however, the application of this technique in the general dental practice still not popular and it is limited to the academic and researches fields. Thus, this review was designed to summarize the current evidence about using aPDT as adjunctive to NSPT for treating periodontitis cases in adult subjects.

Methods

Focused question

The PICO question for this systematic review was is using single episode of aPDT as adjunct to NSPT for adults affected by periodontitis can improve clinical outcomes, with a minimum 3 months follow up after terminating active treatment, as compared to conventional manual instrumentation?

Search strategy

Three databases were searched including PubMed, ScienceDirect, and Cochrane Library for clinical studies about using aPDT for treating periodontitis. Search matrix using for retrieving the articles was composed of the following MeSH terms: periodontitis OR periodontal disease AND photodynamic therapy OR antimicrobial photodynamic therapy OR Laser. The filtration process focused on original articles only, excluding case reports, case series, reviews, books, short communications, study protocols, and editorials. Any work investigating multiple application of aPDT, laser disinfection, treatment of other conditions such as endodontic problems, caries, and other oral lesions were excluded. In addition, only randomized controlled clinical trials investigating the efficacy of single aPDT application as adjunct to NSPT, during active phase, for periodontitis patients aged >18 years with no history of any systemic diseases and non-smoker with follow up period \geq 3-months were included. These articles must be available as free full-text articles and published in English language in the last 10 years. Search results from the abovementioned databases were checked for removing duplicates, then screened according to title followed by filtration by abstract reading. The final filtered papers were evaluated by full-text reading and used for synthesis of evidence for this study. Search and filtration processes of the articles were independently performed by the authors and the results were checked for consistency using kappa coefficient test. When the results were discussed if they did not reach acceptable level of agreement and the process was repeated. The level of agreement for all steps to retrieve relevant articles was >85% between the two authors.

Outcomes

The periodontal clinical parameters were considered as the primary outcomes for data synthesis. Any other assays (microbiological and immunological) were categorized as secondary outcomes

Results

Search of databases, from 2013 to 2023, resulted in 4104 articles which were screened for removing duplicates (n =213). The articles retrieved from this process was 3891 which were further filtered by sorting out RCT, availability of full-text, and abstract screening which were sought for retrieval (n =85). After excluding 41 articles in the last step, the remaining 44 articles were assessed for eligibility by full-text reading. The total number of reports retrieved final analysis and data synthesis was six (Fig. 1).

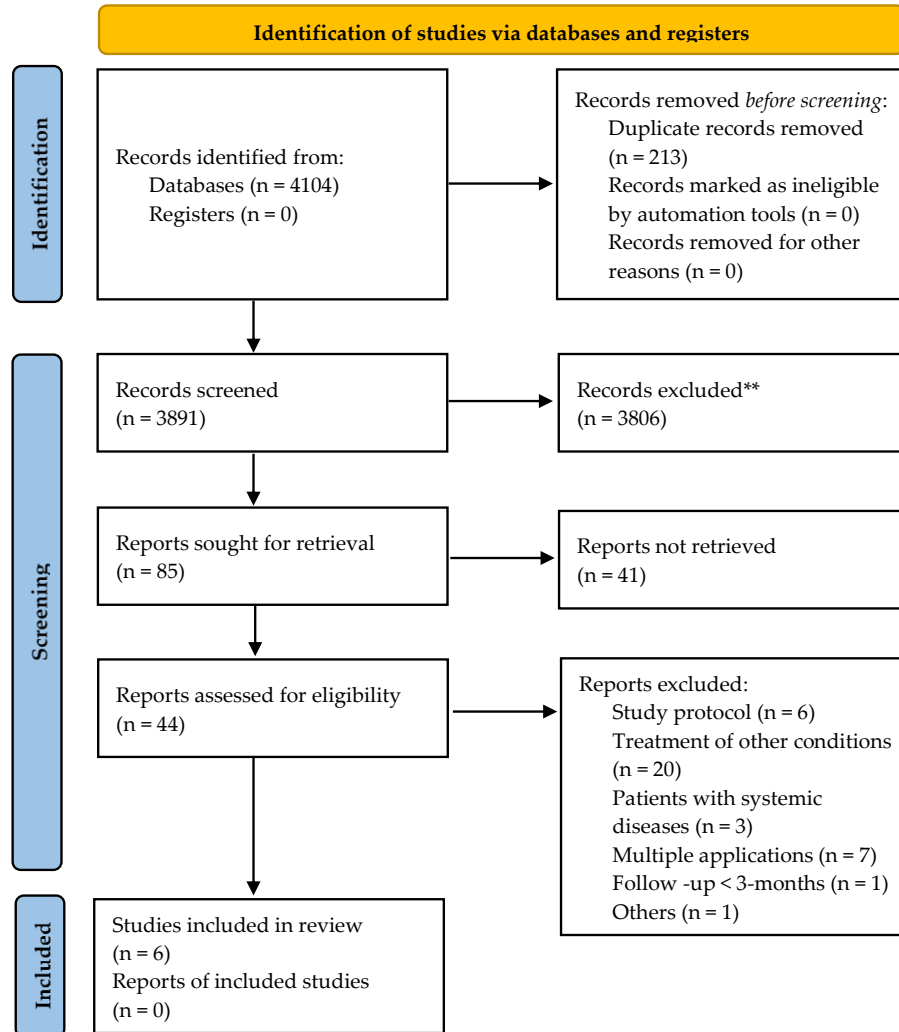


Figure 1: PRISMA flowchart of the study

Table 1: Included studies in the review

| | Author, year |
|---|--------------------------------|
| 1 | Elsadek and Farahat, 2022 [15] |
| 2 | Wadhwa et al., 2021 [16] |
| 3 | Hill et al., 2019 [17] |
| 4 | Bundidpun et al., 2018 [18] |
| 5 | Pulikkotil et al., 2016 [19] |
| 6 | Srikanth et al., 2015 [20] |

Clinical (primary) outcomes

Periodontal clinical parameters (primary outcomes) are illustrated in Table 2. All retrieved articles followed split-mouth design (16-20) except one paper (15) which followed parallel design. With exception of one trial (19) which followed the patients for 3 months after NSPT, all other studies reported 6 months follow up period. Clinical parameters mainly included recording PPD, CAL/RAL, which were shared by all studies, BOP (15-17,19, PI (15,16,18-20) which were measured by using University of North Carolina (UNC)-15 periodontal probe except for Hill et al (17) who used a pressure-sensitive probe. Five studies (16-20) did not put limits to age while one study (15) was designed to investigate the efficacy of aPDT for treating periodontitis in geriatric patients only.

The patients were randomly divided into two groups; control which was treated non-surgically by scaling and root planing (SRP) and test which received, in addition to SRP, aPDT consisting of photosensitizer (PS) dye activated with light of certain wavelength. Indocyanine green (ICG) was used as PS in three studies (16,17,20), methylene blue by two studies (15,19), and phenothiazine chloride by one study (18). The concentrations of PS were not consistent across selected studies. For ICG, Wadhwa et al (16) used 0.25mg/ml, Hill and coauthors (17) used 0.1mg/ml, while Srikanth et al (20) used 5mg/ml. Concentration of methylene blue used by Elsadek and Farahat (15) was 0.005% while the other study (19) did not report the concentration used. The light source used for activating PS also showed variations in wavelength and source. In brief, diode laser with a wavelength 670nm and 660nm was used to activate methylene blue and phenothiazine chloride, respectively (15,18). While ICG was activated by a diode laser with 810nm wavelength. Inconsistency was also evident with the time for leaving PS in the periodontal pocket ranging from 10min (16), 1min(17-19). Two studies (15,20) did not mention the time for allowing absorption of PS dye by the bacteria. The reported exposure time of PS to light source for activation was 5s (16,20), 10s (18,19), and 20s (17). For aPDT group, the periodontal clinical outcomes at the endpoint of the studies either showed significant improvement in these parameters (15,20) or was limited to bleeding scores and gingival inflammation (18,19) or no significant difference (16,17) in comparison to controls.

Secondary outcomes

Microbiological and immunological assays (secondary outcomes) are summarized in Table 3. Four studies (16,17,19,20) collected subgingival biofilm samples for microbiological analysis. While only two studies (15,20) included immunological assays to assess the outcomes of aPDT. The sample collection was performed at baseline, 3 and months after NSPT by two studies (15,16). Pulikkotil et al (19) collected the samples at baseline, immediately after NSPT, 7 days, 1 month, and 3 months after NSPT, while the collection was planned at baseline, immediately after SRP, and after 1 week by another study (20). All subgingival biofilm samples were collected by inserting paper points into the depth of periodontal pockets until minimal resistance was felt. However, the collection time varied from 20s (16), 30s (17,19,20) and the samples either pooled (17,19) or assayed separately for each site (16,20). The microbiological assays ranged from using polymerase chain reaction (17,19), anaerobic culture technique (16), and confocal microscopy for counting viable bacteria (20). Gingival crevicular .

Table 2: Clinical (primary) outcomes of using antimicrobial photodynamic therapy as adjunctive to non-surgical periodontal therapy

| Author, year | Aims | Design/sample | Clinical parameters | Interventions*, † | Outcomes |
|--------------------------------|---|---|---|---|---|
| Elsadek and Farahat, 2022 (15) | To explore the efficacy of PDT as an adjunct to SRP in the treatment of periodontitis | • Parallel, 2-arms with 3- and 6-months follow-up • 60 patients. aPDT group (13 | PI, BOP, PPD, and CAL Measured by UNC-15 | Both groups received a single session of SRP using both the hand instruments and ultrasonic piezoelectric scaler. Periodontal | After 3 months, PI and BOP were significantly improved in aPDT group in |

| | | | | | |
|-------------------------------------|--|--|---|--|---|
| | among geriatric patients | male, 17 female), mean age 68.4±2.8 years. Control group (15 male, 15 female), mean age 66.1±3.3 years <ul style="list-style-type: none"> • Periodontitis stage 3, grade C, PPD >5 mm, presence of bleeding, CAL >5mm, and >10 occluding pairs | periodontal probe | pockets in test group received additional aPDT Settings: <ul style="list-style-type: none"> • PS: Methylene blue (0.005%) • Activation: Diode laser HELBO® (670nm), spot area: 0.028cm², density: 1.1W/cm², power output: 100mW and 150mW • Exposure time: Not reported | comparison with SRP group After 3 and 6 months, significantly higher PPD reduction and CAL gain in aPDT group in comparison with SRP group |
| Wadhwa et al., 2021 ⁽¹⁶⁾ | To evaluate the clinical and microbiological effects of ICG-mediated aPDT as an adjunct to NSPT of periodontitis | <ul style="list-style-type: none"> • Split-mouth, single blind with 3- and 6-months follow-up • 50 patients (22 male and 8 female), mean age 46±7.1 years • Moderate generalized periodontitis with > 30% sites involved; ≥ 2 interproximal sites with clinical attachment loss ≥ 4mm (not on same tooth), or ≥ 2 interproximal sites with PPD ≥ 5mm | PI, GI, SBI, PPD, and RAL Measured by UNC-15 periodontal probe | Full-mouth SRP using piezoelectric ultrasonic/hand scalers and Gracey curettes. Test sites additionally received aPDT Settings: <ul style="list-style-type: none"> • PS: ICG (0.25mg/ml) and left for 10min in the pocket • Activation: GaAlAs diode laser (810nm) in a contact mode and a continuous wave motion at 0.5 W power • Exposure time: 5s/site | No significant differences were observed between the two groups at the same time points |
| Hill et al., 2019 ⁽¹⁷⁾ | To evaluate the clinical efficacy of using ICG-mediated aPDT as an adjunct to NSPT of periodontitis | <ul style="list-style-type: none"> • Split-mouth, single blind with 3- and 6-months follow-up • 20 patients (17 female, 3 male), mean age 61.1 years • Periodontitis with at least one site with PPD >4mm in each quadrant affecting with at least one single | BOP, PPD, GR, and RAL Measured by a pressure-calibrated probe (Click-probe®) | SRP with a piezoelectric ultrasonic system and Gracey-curettes. Test sites received an additional PDT Settings: <ul style="list-style-type: none"> • PS: ICG (0.1mg/ml) which was left for 1min • Activation: Diode laser, 808nm, using an intrasulcular fiber (Ø=300µm), output power: 100mW, pulse repetition rate: 2kHz. | Clinical parameters did not show significant differences between test and control groups |

| | | | | | |
|---|---|---|--|--|--|
| | | tooth and one multirooted tooth involved | | Irradiation dose 2829J/cm ² per pocket • Exposure time: 20s/site | |
| Bundidpun et al., 2018 ⁽¹⁸⁾ | To evaluate the changes of periodontal clinical parameters after PDT (single session) as an adjunct to NSPT | <ul style="list-style-type: none"> • Split-mouth with 1 month, 3- and 6-months follow-up • 20 patients (7 male, 13 female), mean age 47.25 ± 8.91 years • Moderate to severe generalized periodontitis (n=20) with ≥20 teeth, ≥1 molar in each quadrant with a ≥4 teeth, ≥2 teeth and one molar tooth presented with PPD > 6mm in each quadrant | PI, GI, GBI, PPD, and CAL Measured by UNC-15 periodontal probe | Control sites treated with SRP, while test sites received PDT 1 week after SRP Settings: • PS: Phenothiazine chloride (HELBO® Photodynamic Systems) left for 1min in the pocket • Activation: Diode laser (660nm, output power; 100mW) • Exposure time: 10s/site | No significant difference in clinical parameters between the two groups after 1 month, 3 and 6 months after NSPT except for GI and GBI which were significantly lower in test side as compared to control after 3 and 6 months |
| Pulikkotil et al., 2016 ⁽¹⁹⁾ | To evaluate the efficacy of PDT in reducing Aa in periodontitis patients | <ul style="list-style-type: none"> • Split-mouth with follow up immediately, 7 days, 1 month, and 3 months after NSPT • 16 patients, mean age 45.2±6.7 years • Aggressive periodontitis with bilateral periodontal pockets measuring ≥ 5mm in ≥3 sites in different posterior teeth with a minimum of 20 teeth | PI, BOP, PPD, and CAL Measured by UNC-15 color coded periodontal probe | Control sites treated with SRP, while test sites received SRP +PDT Settings: • PS: methylene blue, left in pocket for 1min then excess washed with sterile water • Activation: light-emitting diode (LED, Fotosan®) with a red spectrum, frequency 628Hz • Exposure time: 10s of light with the blunt tip followed by 10s of the periodontal tip | Intergroup comparisons showed only significant difference in BOP in favor of aPDT after 3 months |
| Srikanth et al., 2015 ⁽²⁰⁾ | To evaluate the effect of ICG as an adjunct to NSPT in the treatment of periodontitis | <ul style="list-style-type: none"> • Split-mouth (premolars and molars), double blind, with 1 week, 3 and 6 months follow up • Periodontitis (n=27) having ≥2 | PI, MGI, PPD, and CAL Measured by UNC-15 color coded periodontal probe | Full-mouth SRP for control and test groups. The latter received additional aPDT Settings: • PS: 0.5ml (5mg/ml) ICG | All clinical parameters, except PPD, significantly improved in association with ICG group as compared to |

| | | |
|---|---|--|
| periodontal pockets (PPD ≥5mm) with radiographic evidence of bone loss per quadrant | <ul style="list-style-type: none"> • Activation: Diode laser (810nm) continuous beam wave mode with 0.7 W output • Exposure time: 5s/site | control after 3 and 6 months following NSPT. This suggested the beneficial effect of aPDT as adjunct to periodontal treatment of periodontitis |
|---|---|--|

Abbreviations: aPDT: antimicrobial photodynamic therapy, NSPT: nonsurgical periodontal therapy, SRP: scaling and root planing, PS: photosensitizer, PI: plaque index, GI: gingival index, SBI: sulcus bleeding index, GBI: gingival bleeding index, PPD: probing pocket depth, GR: gingival recession, CAL: clinical attachment level, RAL: relative attachment level, UNC-15: University of North Carolina no.15, ICG: indocyanine green, GaAlAs: Gallium Aluminium Arsenide, Aa: *Aggregatibacter actinomycetemcomitans*

† Groups for all studies: control received SRP only, while test group received SRP + aPDT

* All techniques used apico-coronal direction during application into periodontal pockets by a disposable blunt end cannula, overfilling the pocket and removing the excess

Table 3. Microbiological and immunological (secondary) outcomes of using antimicrobial photodynamic therapy as adjunctive to non-surgical periodontal therapy

| Author, year | Aims | Sample | Assays | Outcomes |
|---|--|---|---|--|
| Elsadek and Farahat, 2022 ⁽¹⁵⁾ | To explore the efficacy of aPDT as an adjunct to SRP in the treatment of periodontitis among geriatric patients | <ul style="list-style-type: none"> • GCF was sampled from the deepest part of the periodontal pocket by inserting paper points (Periopaper, Pro Flow, Amityville, NY, USA) for 30s. GCF volume was determined by a calibrated electronic device (Periotron 6000, Amityville, NY, USA) • Samples were collected at baseline, 3 and 6 months after NSPT | Levels of GCF IL-1β and IL-6 were quantified by using commercially available ELISA kits | For test group, there was no significant difference in the IL-1β levels between both the groups. The same trend was followed by IL-6 at 3 months. However, the reduction in the IL-6 was maintained until 6 months of re-evaluation. |
| Wadhwa et al., 2021 ⁽¹⁶⁾ * | To evaluate the clinical and microbiological effects of ICG-mediated aPDT as an adjunct to NSPT of periodontitis | <ul style="list-style-type: none"> • Subgingival biofilm samples were collected by inserting a sterile paper point (ISO 30) for 20s into the deepest point of each periodontal pocket • Samples were collected at baseline, 3 and 6 months after NSPT | The four-quadrant streak method was used to spread the inoculum across the plate. The inoculated brain heart infusion agar plates, augmented with vitamin K & hemin, were anaerobically cultured at 37°C for 5 days then TVAC and CFU were determined | Sites treated with ICG-mediated aPDT exhibited significantly lower CFU than controls 3 and 6 months after NSPT |
| Hill et al., 2019 ⁽¹⁷⁾ | To evaluate the clinical efficacy | Subgingival biofilm samples were | Quantitative analysis of A.a., P.g., | Following aPDT, there was a significant |

| | | | | |
|---|---|---|---|--|
| | of using ICG-mediated aPDT as an adjunct to NSPT of periodontitis | collected by inserting a sterile paper point (ISO 40) for 30s. The sampled paper tips were placed quadrant-wise as pooled samples into microreaction tubes | P.i., T.f. and T.d. was determined using rt-PCR | reduction in P.i. and T.d. compared to control group |
| Pulikkotil et al., 2016 ⁽¹⁹⁾ | To evaluate the efficacy of aPDT in reducing Aa in periodontitis patients | <ul style="list-style-type: none"> • Sterile paper points (ISO 30) were inserted to the depth of the pocket. After remaining for 30s, all the points were pool transferred to a sterile microtube to be stored at -20°C • Samples were collected at baseline, immediately after NSPT, 7 days, 1 month, and 3 months after NSPT | Quantification of Aa in the treated periodontal pocket was undertaken using rt-PCR | No difference in the bacterial quantity was detected for both intragroup and intergroup analysis at all time points |
| Srikanth et al., 2015 ⁽²⁰⁾ | To explore the efficacy of PDT as an adjunct to SRP in reducing the % of viable bacteria and host tissue injury | <ul style="list-style-type: none"> • Subgingival biofilm samples were collected by inserting a sterile paper point for 30s into the periodontal pocket • GCF samples were collected by using filter paper circles (0.6mm) placed in the pocket for 30s then immediately transferred to a tube containing 100µl DW and stored at -30°C • Both samples were collected at baseline, immediately after SRP, and after 1 week | <ul style="list-style-type: none"> • Bacterial viability kit (LIVE/DEAD BacLight Bacterial Viability Kit, Invitrogen) used to stain the bacteria which were quantitatively assayed using confocal microscopy images capture at 488nm and 532nm laser excitation • Quantitative total LDH by using a commercially available kit (LDH-Cytotoxicity Assay Kit II, Abcam) to indicate the relative cell viability and plasma membrane integrity | <ul style="list-style-type: none"> • aPDT group demonstrated significantly lower % of viable bacteria immediately after SRP and 1 week following SRP than control group • LDH activity showed no significant difference between the two group at any time point of the study |

Abbreviations: aPDT: antimicrobial photodynamic therapy, SRP: scaling and root planing, ICG: indocyanine green, NSPT: non-surgical periodontal therapy, TVAC: total viable anaerobic count, CFU: colony forming unit, LDH: , GCF: gingival crevicular fluid, rt-PCR: real-time chain reaction, LDH: Lactate dehydrogenase A.a. *Aggregatibacter actinomycetemcomitans*, P.g.: *Porphyromonas gingivalis*, P.i.: *Prevotella intermedia*, T.f.: *Tannerella forsythia*, T.d.: *Treponema denticola*

fluid (GCF) samples were collected for assaying levels of IL-1β and IL-6 ⁽¹⁵⁾ or measuring LDH activity to estimate the cellular integrity and viability ⁽²⁰⁾.

In general, the results indicated better microbiological outcomes in favor of site treated with adjunctive aPDT as compared to control group. This was reflected by significantly lower colony forming units ⁽¹⁶⁾, significant reduction in periodontal pathogens *Prevotella intermedia* and *Treponema denticola* ⁽¹⁷⁾ and significant decrease in percentage of viable bacteria ⁽²⁰⁾. However, one study ⁽¹⁹⁾ showed no significant difference in the bacterial quantity between the two groups. Elsadek and Farahat ⁽¹⁵⁾ reported limited effect of adjunctive aPDT on the level of GCF-IL-6 at the end of the trial. Srikanth et al ⁽²⁰⁾ demonstrated that LDH activity was not significantly altered between test and control groups suggesting the safety of aPDT as adjunctive therapy.

Discussion

The inherited limitations of NSPT drew attention towards introducing other adjunctive therapies such as antimicrobials⁽⁷⁾, antioxidants⁽⁸⁾, probiotics⁽²¹⁾, ozone⁽²²⁾, and PDT⁽⁹⁾. The current systematic review aimed to investigate whether a single application of aPDT as adjunct to NSPT during treatment of periodontitis cases is beneficially affecting periodontal clinical outcomes as compared to conventional NSPT. Generally, the results showed that both modalities significantly improved clinical parameters with no significant differences between the test and control group. However, aPDT showed better improvement in clinical parameters dedicated to measure bleeding and gingival inflammation scores. This was associated with reduction in the count and quantity of periodontal pathogens collected from subgingival dental biofilm samples.

The analysis of data obtained from the selected articles showed heterogeneity in type and concentration of PS, methods followed for measuring outcomes, techniques/time for sampling/assaying biological samples, laser type, exposure time, and age of the participants. These variations made the attempt to conduct a meta-analysis not possible. PPD and CAL were the shared clinical parameters measured by all six studies. Two reports^(15,20) showed improvement in CAL while reduction in PPD was only observed in one study⁽¹⁵⁾ when comparing aPDT with controls. The latter study investigated efficacy of aPDT for treating periodontitis in geriatric patients only whom the progression rate i.e., grade of periodontitis is known to be slower than younger counterparts⁽²³⁾ which could alter the results in favor of aPDT. Clinical results were in consistency with previous studies⁽²⁴⁻²⁶⁾ that showed significant reduction of PPD when combining SRP with aPDT after 3 and 6 months. However, another study indicated that only PPD was significantly reduced after 3 months without additional gain of attachment after applying aPDT⁽²⁷⁾. These variations could be attributed to the use of different treatment modalities, sample size, PS, single vs multiple sessions of aPDT, and combination of other variables such as age, source and wavelength of laser used. Additionally, tooth type and severity of periodontitis seem to be of great influence on the outcomes. The success rate of NSPT for moderately deep pockets (4 to 6mm) in anterior teeth could exceed 85%, however, the success of the same treatment for the same pocket depth could decrease to 47% in posterior teeth and further reduced when furcation area is involved⁽⁵⁾. Therefore, these factors should be considered when assessing the success of adjunctive aPDT in the future.

Microbiological outcomes were included in four studies^(16,17,19,20) which used different methods such as culture technique⁽¹⁶⁾, PCR^(17,19), and viable bacterial count⁽²⁰⁾. Most of these studies agreed that aPDT significantly reduced the bacterial load after treatment. These finding could be explained by cytotoxic effect of PS which irradiate bacteria and their virulence factors in areas not accessible to hand or ultrasonic scalers such as root concavities and depressions, thereby, minimizing the chance of recolonizing these bacteria in the periodontal pockets. This was evident by significant reduction in bleeding scores and gingival inflammation following application of aPDT^(18,19) which are closely relevant to the presence of pathogenic periodontal bacteria. Persistent presence of bacteria, particularly Gram negative bacteria, is known to compromise the epithelial coherence resulting in microulceration of the epithelial pocket lining⁽²⁸⁾. Application of aPDT could resulted in reducing the load of these bacteria at baseline, decreasing the chance of repopulation of pocket, hence, restoring epithelial integrity. Interestingly, aPDT did not show any detectable effect on the viability of beneficial commensals such as *Streptococcus sanguinis* or *Streptococcus mitis*, while CFU of pathogenic bacteria *Porphyromonas gingivalis*, *Fusobacterium nucleatum*, and *Aggregatibacter actinomycetemcomitans* significantly reduced after exposure to light-excited PS⁽²⁹⁾. This selectivity in antimicrobial activity of aPDT represent an advantage over antibiotics commonly prescribed as adjunct to periodontal therapy such as amoxicillin and metronidazole which target all bacterial species without exceptions. Hill and coauthors⁽¹⁷⁾ demonstrated that ICG-mediated aPDT significantly reduced *P. intermedia* and *T. denticola*, a member of red complex, 6 months after NSPT. However, this did not tip the balance of clinical outcomes in favor of aPDT group in comparison with control. This could be due to failure in eliminating other pathobionts such as *F. nucleatum* and *P. gingivalis*

which are known to be associated with dysbiosis of subgingival biofilm and the destructive events of periodontitis⁽¹⁾. Increased inflammatory cytokines is a well-recognized event during periodontitis⁽³⁰⁾. Indeed, mechanical removal of pathogenic biofilm reverse the levels of these cytokines to healthy state which is was demonstrated by one of the studies in this review⁽¹⁵⁾ whiout any difference between the test and control groups. Therefore, earlier assay of interleukins is advised to closely monitor any changes associated with treatment rather than late measurement during which the cytokines levels return to almost norml.

The results also demonstrated that aPDT was tissue-friendly and safe to be used in combination with SRP. This was evident by one of the studies⁽²⁰⁾ which showed that LDH activity was not significantly different between SRP and SRP + aPDT. This assay is used to indicate the cellular viability and integrity of the plasma membrane. The cytotoxic effect of PS was previously investigated *in vitro* on mammalian oral cells (gingival fibroblast and periodontal ligament cells). The results showed that the cytotoxicity of aPDT was equal to that of standard antiseptics routinely used as a mouth rinse^[29]. The findings of this review are not enough to report a solid conclusion about the efficacy of adjunctive aPDT and the final word requires conducting further longer term highly standardized RCT. In addition, the evaluation of this therapy must bot be limited to clinical parameters but including other outcomes such as quality of life and the impact on systemic conditions such as glyceic state.

Conclusion

Retrieved data from this study indicated that adjunctive aPDT has a potential beneficial effect on short-term mainly reflected by improving bleeding scores and microbiological outcomes for patients with periodontitis. However, longer term advantage was not evident as compared to conventional periodontal therapy. SRP remains the gold-standard technique for treating periodontitis and restoring homeostasis of periodontal tissues. The heterogeneity of methods and discrepancies of results postponed the final decision about using aPDT for treating periodontal disease until concrete conclusion is reached by further RCT taking in consideration optimal combination of laser settings and PS.

Conflict of interest

The authors have no conflicts of interest to declare.

Author contributions

ARA; study conception and design. ARA and ZRA; data retrieval. ARA and ZRA; Methodology. ARA and ZRA; filtering data and interpretation of results. ZRA; original draft manuscript preparation. ARA and ZRA; Writing - review & editing. All authors reviewed the results and approved the final version of the manuscript to be published.

Acknowledgement and funding

No grant or financial support was recieved from any governmental or private sector for this study

Informed consent

N/A

References

1. Abdulkareem AA, Al-Taweel FB, Al-Sharqi AJB, Gul SS, Sha A, Chapple ILC. Current concepts in the pathogenesis of periodontitis: from symbiosis to dysbiosis. J Oral Microbiol 2023, 15, 2197779. [\(Crossref\)](#)

2. Takedachi M, Shimabukuro Y, Sawada K, Koshimizu M, Shinada K, Asai H, et al. Evaluation of periodontitis-related tooth loss according to the new 2018 classification of periodontitis. *Scientific Reports* 2022, 12, 11893. [\(Crossref\)](#)
3. Comprehensive periodontal therapy: a statement by the American Academy of Periodontology *. *J Periodontol* 2011, 82, 943-949. [\(Crossref\)](#)
4. Albeshri S, Greenstein G. Efficacy of nonsurgical periodontal therapy for treatment of periodontitis: practical application of current knowledge. *Gen Dent* 2022, 70, 12-19. 35993928.
5. Van der Weijden GAF, Dekkers GJ, Slot DE. Success of non-surgical periodontal therapy in adult periodontitis patients: A retrospective analysis. *Int J Dent Hyg* 2019, 17, 309-317. [\(Crossref\)](#)
6. Waerhaug J. Healing of the dento-epithelial junction following subgingival plaque control. II: As observed on extracted teeth. *J Periodontol* 1978, 49, 119-134. [\(Crossref\)](#)
7. Teughels W, Feres M, Oud V, Martín C, Matesanz P, Herrera D. Adjunctive effect of systemic antimicrobials in periodontitis therapy: A systematic review and meta-analysis. *J Clin Periodontol* 2020, 47 Suppl 22, 257-281. [\(Crossref\)](#)
8. Castro MML, Duarte NN, Nascimento PC, Magno MB, Fagundes NCF, Flores-Mir C, et al. Antioxidants as Adjuvants in Periodontitis Treatment: A Systematic Review and Meta-Analysis. *Oxid Med Cell Longev* 2019, 2019, 9187978. [\(Crossref\)](#)
9. Park D, Choi EJ, Weon KY, Lee W, Lee SH, Choi JS, et al. Non-Invasive Photodynamic Therapy against -Periodontitis-causing Bacteria. *Scientific Reports* 2019, 9, 8248. [\(Crossref\)](#)
10. Castano AP, Demidova TN, Hamblin MR. Mechanisms in photodynamic therapy: part one-photosensitizers, photochemistry and cellular localization. *Photodiagnosis Photodyn Ther* 2004, 1, 279-293. [\(Crossref\)](#)
11. Kömerik N, Nakanishi H, MacRobert AJ, Henderson B, Speight P, Wilson M. In vivo killing of *Porphyromonas gingivalis* by toluidine blue-mediated photosensitization in an animal model. *Antimicrob Agents Chemother* 2003, 47, 932-940. [\(Crossref\)](#)
12. Chan Y, Lai CH. Bactericidal effects of different laser wavelengths on periodontopathic germs in photodynamic therapy. *Lasers Med Sci* 2003, 18, 51-55. [\(Crossref\)](#)
13. Boehm TK, Ciancio SG. Diode laser activated indocyanine green selectively kills bacteria. *J Int Acad Periodontol* 2011, 13, 58-63.
14. Stájer A, Kajári S, Gajdács M, Musah-Eroje A, Baráth Z. Utility of Photodynamic Therapy in Dentistry: Current Concepts. *Dent J (Basel)* 2020, 8. [\(Crossref\)](#)
15. Elsadek MF, Farahat MF. Effectiveness of photodynamic therapy as an adjunct to periodontal scaling for treating periodontitis in geriatric patients. *Eur Rev Med Pharmacol Sci* 2022, 26, 1832-1838. [\(Crossref\)](#)
16. Wadhwa A, Mallapragada S, Sharma P. Novel indocyanine green mediated antimicrobial photodynamic therapy in the management of chronic periodontitis - A randomized controlled clinico-microbiological pilot study. *J Oral Biol Craniofac Res* 2021, 11, 57-62. [\(Crossref\)](#)
17. Hill G, Dehn C, Hinze AV, Frentzen M, Meister J. Indocyanine green-based adjunctive antimicrobial photodynamic therapy for treating chronic periodontitis: A randomized clinical trial. *Photodiagnosis Photodyn Ther* 2019, 26, 29-35. [\(Crossref\)](#)
18. Bundidpun P, Srisuwantha R, Laosrisin N. Clinical effects of photodynamic therapy as an adjunct to full-mouth ultrasonic scaling and root planing in treatment of chronic periodontitis. *Laser Ther* 2018, 27, 33-39. [\(Crossref\)](#)
19. Pulikkotil SJ, Toh CG, Mohandas K, Leong K. Effect of photodynamic therapy adjunct to scaling and root planing in periodontitis patients: A randomized clinical trial. *Aust Dent J* 2016, 61, 440-445. [\(Crossref\)](#)
20. Srikanth K, Chandra RV, Reddy AA, Reddy BH, Reddy C, Naveen A. Effect of a single session of antimicrobial photodynamic therapy using indocyanine green in the treatment of chronic periodontitis: a randomized controlled pilot trial. *Quintessence Int* 2015, 46, 391-400. [\(Crossref\)](#)

21. Ho SN, Acharya A, Sidharthan S, Li KY, Leung WK, McGrath C, et al. A Systematic Review and Meta-analysis of Clinical, Immunological, and Microbiological Shift in Periodontitis After Nonsurgical Periodontal Therapy With Adjunctive Use of Probiotics. *Journal of Evidence Based Dental Practice* 2020, 20, 101397. [\(Crossref\)](#)
22. Deepthi R, Bilichodmath S. Ozone Therapy in Periodontics: A Meta-analysis. *Contemp Clin Dent* 2020, 11, 108-115. [\(Crossref\)](#)
23. Tonetti MS, Greenwell H, Kornman KS. Staging and grading of periodontitis: Framework and proposal of a new classification and case definition. *J Periodontol* 2018, 89 Suppl 1, S159-s172. [\(Crossref\)](#)
24. Azaripour A, Dittrich S, Van Noorden CJF, Willershausen B. Efficacy of photodynamic therapy as adjunct treatment of chronic periodontitis: a systematic review and meta-analysis. *Lasers Med Sci* 2018, 33, 407-423. [\(Crossref\)](#)
25. Akram Z. How effective is adjunctive antimicrobial photodynamic therapy in treating deep periodontal pockets in periodontal disease? A systematic review. *J Investig Clin Dent* 2018, 9, e12345. [\(Crossref\)](#)
26. Pardo A, Butera A, Giordano A, Gallo S, Pascadopoli M, Scribante A, et al. Photodynamic Therapy in Non-Surgical Treatment of Periodontitis: A Systematic Review and Meta-Analysis. *Applied Sciences* 2023, 13, 1086. [\(Crossref\)](#)
27. Atieh MA. Photodynamic therapy as an adjunctive treatment for chronic periodontitis: a meta-analysis. *Lasers Med Sci* 2010, 25, 605-613. [\(Crossref\)](#)
28. Kazem NM, Abdulkareem AA, Milward MR. Salivary E-cadherin as a biomarker for diagnosis and predicting grade of periodontitis. *J Periodontal Res* 2023, 58, 715-722. [\(Crossref\)](#)
29. Park D, Kim M, Choi JW, Baek JH, Lee SH, Baek K. Antimicrobial photodynamic therapy efficacy against specific pathogenic periodontitis bacterial species. *Photodiagnosis Photodyn Ther* 2020, 30, 101688. [\(Crossref\)](#)
30. Abdullameer MA, Abdulkareem AA. Salivary interleukin-1 β as a biomarker to differentiate between periodontal health, gingivitis, and periodontitis. *Minerva Dent Oral Sci* 2023, 72, 221-229. [\(Crossref\)](#)

العنوان: فعالية جلسة علاج ضوئي ديناميكي واحدة مضادة للميكروبات كمساعد لعلاج اللثة غير الجراحي على النتائج السريرية لمرضى التهاب اللثة. **مراجعة منهجية الباحثون:** أحمد رمزي عبدالخالق، زيد رمزي عبدالخالق **المستخلص:**

الخلفية: التهاب دواعم السن هو مرض متعدد العوامل ومتعدد المسببات يرتبط بأحداث مدمرة لدواعم السن. يعتبر علاج اللثة غير الجراحي أسلوبًا فعالاً ومعياريًا ذهبيًا لعلاج هذا المرض. ومع ذلك، يمكن أن تعيق عدة متغيرات معدل النجاح. أظهر الجمع بين العلاج الديناميكي الضوئي المضاد للميكروبات مع علاج اللثة غير الجراحي نتائج واعدة ولكن الأدبيات المتاحة تظهر اختلافات في النتائج. الهدف: ما إذا كان استخدام حلقة واحدة من العلاج الديناميكي الضوئي المضاد للميكروبات كمساعد لعلاج اللثة غير الجراحي للبالغين المصابين بالتهاب اللثة يمكن أن يحسن النتائج السريرية، مع متابعة لمدة 3 أشهر على الأقل بعد إنهاء العلاج النشط، مقارنة بالأدوات البديوية التقليدية؟

الطرق: تم البحث في ثلاث قواعد بيانات (Cochrane Library، ScienceDirect، PubMed) لاسترداد المقالات ذات الصلة. تتكون مصفوفة الكلمات الرئيسية المستخدمة في عملية البحث من المصطلحات التالية: التهاب اللثة أو أمراض اللثة والعلاج الديناميكي الضوئي أو العلاج الديناميكي الضوئي المضاد للميكروبات أو الليزر. النتائج: تم استرداد إجمالي 4104 مقالة من عملية البحث خلال السنوات العشر الماضية. بعد إزالة التكرارات وتطبيق المرشحات، أصبحت 44 مقالة مؤهلة لقراءة النص الكامل. أسفرت الخطوة الأخيرة عن 6 تجارب معشاة ذات شواهد تم استخدامها لتجميع البيانات. الاستنتاجات: أشارت البيانات المستردة من هذه الدراسة إلى أن العلاج الديناميكي الضوئي المضاد للميكروبات المساعد له تأثير مفيد محتمل على المدى القصير والذي ينعكس بشكل رئيسي من خلال تحسين درجات الزيف والنتائج الميكروبيولوجية للمرضى الذين يعانون من التهاب اللثة. ومع ذلك، لم تكن الميزة على المدى الطويل واضحة بالمقارنة مع علاج اللثة التقليدي. يُنصح بإجراء المزيد من الدراسات لاستخلاص نتيجة قوية حول استخدام العلاج الديناميكي الضوئي المضاد للميكروبات كعامل مساعد لعلاج اللثة غير الجراحي

