

Research Article

# Local application of *Opuntia ficus-indica* / *Punica granatum* oils on cutaneous wound healing: a histochemical study

Enas Yousif Al-Zubaidy <sup>1\*</sup>, Ban A. Ghani <sup>1</sup>, Nurul Ruziantee Ibrahim <sup>2</sup>

1 Department of Oral Diagnosis, College of Dentistry, University of Baghdad, Baghdad, Iraq.

2 DDS (USM), DCLinDent, Oral Pathology, Otago, International Islamic University Malaysia

\*Corresponding author: [golden87rose@yahoo.com](mailto:golden87rose@yahoo.com)

Received date: 15-06-2022

Accepted date: 05-09-2022

Published date: 15-12-2023



**Copyright:** © 2022 by the authors.

Submitted for possible open access publication under the terms and conditions of the Creative Commons Attribution (CC BY) license (<https://creativecommons.org/licenses/by/4.0/>).

<https://doi.org/10.26477/jbcd.v35i4.3508>

**Abstract:** Background: The healing process involves the restoration of the body's structural integrity. The extracellular matrix, blood cells, cytokines, and growth factors are all involved in this dynamic, intricate, multicellular process. Hemostasis, the inflammatory phase, the proliferative phase, and the maturation phase are all included. *Opuntia ficus-indica* oil (OFI) and *Punica granatum* (PGS) oil are extensively used natural treatments that are regarded as advantageous for their sedative, spasmolytic, and anti-inflammatory properties, as well as for angiogenesis promotion, fibroblast increase, collagen production and deposition, and extracellular-matrix remodeling. Materials and methods: Twenty-four New Zealand rabbits were used. Four circular wounds were induced on their dorsum skin with a sterile biopsy punch (8 mm in diameter). A wound on the upper right side left with no treatment healed spontaneously. A wound on the upper left side was treated with OFI. A wound on the lower right side was treated with PGS oil. Finally, the lower left-side wound was treated with a combination of OFI and PGS oils. After each healing period (days 3, 7, and 14), animals were sacrificed to collect specimens by cutting the skin at the edges of the wound by about 5 mm. Results: Collagen formation was faster in the experimental groups than in the control group. Conclusion: Among the experimental groups, the joint local application of OFI and PGS oils was the most effective in improving wound healing by promoting the synthesis of matrix collagen compared with controls.

**Keywords:** *Opuntia ficus-indica* oil, *Punica granatum* seed oil, wound healing.

## Introduction

The biological process of wound healing is intricate and occurs in all human tissues and organs. This process involves several cell types, including keratinocytes, neutrophils, macrophages, lymphocytes, fibroblasts, and endothelial cells <sup>(1)</sup>. Throughout the skin wound-healing process, several cellular and molecular mediators are activated to defend and eliminate pathogens from the injured area, thereby establishing a new environment where cells multiply and eventually seal the wound. Hemostasis, inflammation, proliferation, and tissue remodeling are examples of processes that occur in overlapping stages. Each step orchestrates the entire process with a unique pattern of dominating cell extracellular matrix (ECM) organization, cytokines, growth factors, and enzyme activation <sup>(2)</sup>. Keratinocytes, a crucial cellular element of the epidermis, are in charge of healing damaged epidermis through epithelialization <sup>(3)</sup>. Therapeutic therapies are used for healing, and innovative treatments have been developed using synthetic, chemical, and biological technology. Wound healing is a natural process, and medicinal herbs and bioactive compounds are used as substitute therapies to accelerate wound healing and re-epithelialization <sup>(4)</sup>.

Pomegranate components comprise antioxidant, anticarcinogenic, antibacterial, and anti-inflammatory components. They have been shown in studies conducted over the past ten years to have beneficial qualities <sup>(5)</sup>. The majority of pomegranate seeds and oils normally contain unsaturated fatty acids in their unconjugated condition, except for a limited number that have conjugated, double, triple, or tetraene links. Examples of conjugated double and triple bonds are linolenic acids. Researchers have

examined whether oil contains conjugated fatty acids. Conjugated fatty acids are more abundant in pomegranate seed oil <sup>(6)</sup>. *Opuntia ficus-indica* (OFI), a medicinal plant belonging to the family Cactaceae, has long been used to treat several ailments, including wound healing. In animal models, several extracts from various sections of OFI including stems and cladodes have demonstrated promising wound-healing effects. OFI has wound-healing qualities boosted by the oil's ability to self-emulsify into nanodroplets. Its anti-inflammatory, procollagen, and angiogenic qualities can account, at least in part, for these observed activities <sup>(7)</sup>. Both of these compounds have the potential to operate as antioxidant molecules by removing reactive species from the environment (such as superoxide anion, hydroxyl, and sulfate radicals) and enhancing the body's endogenous production of antioxidant molecules. Superoxide dismutase, glutathione, and myeloperoxidase are examples of antioxidants produced by the body. Their levels may change owing to the presence of chemicals generated from natural sources <sup>(8)</sup>.

In relation to the aforementioned properties, the present study aimed to assess the cellular proliferative activity of wounds and to evaluate the density of collagen fiber in wounds treated with opuntia ficus-indica oil / Punica Granatum seed oil in rabbits.

### Materials and Methods

Masson tricolor treated skin samples, can effectively stain collagen fibers blue with dye have aniline. The Masson's trichrome-stained slides were analyzed using a polarized light microscope (Leica, Germany) and a software image analyzer (Video Test-Master 4.0 software) to determine the intensity of the blue hue, which represents collagen density. At 40 magnification, the collagen density was measured under the wound area in comparison to the normal dermis. The mean of the collagen values measured in the dermis of healthy individuals was accepted as 100. The mean collagen density under the lesion area for each group was expressed as a percentage relative to the collagen density of the normal dermis.

$$\text{Ratio} = (\text{Average collagen intensity under wound} \div \text{Average collagen intensity of normal dermis}) \times 100$$

### Study design and surgical procedure

The ethical guidelines for using animals in research, as formulated by the College of Dentistry/University of Baghdad (Reference Number: 681 on 11/10/2022), were followed throughout all experimental procedures. Adult male New Zealand rabbits weighing an average of 1.5–2 kg were used. All rabbits were kept in climate-controlled housing with controlled ventilation settings. They were fed a normal diet (pellets) and had easy access to the water supply. Standard separate cages were used to house the animals and fasted before surgery for about 6–8 h. The animals were randomly divided into three main groups (eight rabbits each) according to the healing interval (3, 7, and 14 days). Wounds on the dorsal side of rabbits in the upper right sides were allowed to naturally heal as a control without adding anything even a placebo, whereas remaining wounds on the upper left, lower left, and lower right were treated with OFI oil, PGS, and a combination of the two oils at a 1:1 ratio, respectively using of micro pipit. Before surgical procedures, each animal was weighed to determine the dose of anesthesia required. The animal was then placed on a surgical table, and general anesthesia was induced by intramuscular injection of xylazine 2% (0.4 mg/kg B.W.) plus 50 mg of ketamine HCl, (40 mg/kg B.W.). Hair was removed from the dorsal region. Ethanol (70%) was used to clean the skin. Four circular, full-thickness skin sections of about (1.5 to 2.0) mm of wound were created on the dorsal skin by using an 8 mm biopsy punch. Each lesion was coated with around 5 mm of the surrounding normal tissue, and then a full thickness of skin was removed using a surgical blade. The samples were added with 10% freshly produced formalin for 24 h. then Dehydration of biological samples is an important step in tissue processing. The purpose of dehydration is to remove water from biological samples so that they can be further studied with a light microscope, then, each sample is run through an xylene jar for 30 minutes, and after that Treated tissue samples are dipped in molten paraffin wax. After the paraffin wax solidifies the block is ready for cutting.

### Specimen preparation for histochemical staining

Slides of skin tissue were deparaffinized, placed in a staining jar, and submerged for 45 min at 60 °C in a warm Blouin's solution. After washing the slides, they were exposed to modified Weigert's hematoxylin for 8 min. After immersing in acid fuschin for 5 min to stain the cytoplasm and erythrocytes, they were once again cleaned. Treatment for an additional 10 min with phosphomolybdic acid solution as a mordant was conducted. Then, the slides were immediately immersed in methyl blue solution for 5 min to stain the collagen and fibroblasts, cleaned before being exposed for 1 min to a 1% acetic acid solution, dried out, and transformed in alcohol. The slides were mounted onto a cover slip after being immersed in 100% xylene for one minute before inspection.

#### Statistical analysis

The effects of using OFI and PGS oils separately and in combination on rabbit skin healing were analyzed statistically. Data was made on the Statistical Package for Social Sciences (SPSS) version 26. Only serial numbers were related to the details of the participants and the collected data was managed on a daily base. Data was expressed using mean/standard deviation, and minimum and maximum levels. ANOVA test and post hoc test (LSD test) were used to assess the difference between the studied independent groups. A confidence level of 95% with a P-value equal to or less than 0.05 was considered significant.

#### Results: Histological finding (Masson's trichrome stain)

On day 3, using the modified Masson's trichrome staining, the control group showed very little fibrin network (FN) with numerous areas of blood cell (BC) accumulations, creating a scaffold for fibroblasts. On day 7, the formation of new epithelium (EP), fine collagen fibers (CFs), and hair follicles (HFs) was more prominent. On day 14, CFs, adipose tissue, and HFs were very clear, with keratinized EP on the surface (Figs. 1a–1c).

For the experimental groups on day 3, microphotograph views show an accumulation of new CFs, developing HFs, and new EP on the surface (Fig. 2a). Disorganized CFs were noticed with areas of BC accumulation (Figs. 2b and 2c).

After 7 days, the OFI group showed complete epithelialization, a sealed wound surface, and dense CFs (Fig. 3a). Thickened newly formed EP, and CFs and HFs were remodeled (Fig. 3b). Remodeling CFs, appeared denser with numerous blood vessels (BVs) (Fig. 3c).

On 14 days, microphotograph views showed thickened keratinized EP, CFs, and well-organized BVs in the dermis (Figs. 4a–4c). Skin sections for evaluating CF density (intensity of blue hue, which stands for collagen density) were measured using a polarized light microscope (Leica, Germany) and an image analyzer. At 40× magnification, collagen density was assessed beneath the wound region compared with a healthy dermis. The average collagen levels found in the normal dermis were regarded as being equal to 100. The average collagen densities under the wound area for each group were represented as a percentage compared with the collagen densities of the normal dermis on the post-wounding day.

As shown in Table 1, the mean values of the control and experimental groups peaked on day 14 with prolonged time. The lowest mean values were obtained on day 3. ANOVA test revealed a significant difference among the control and experimental groups on days 3, 7, and 14 ( $p < 0.01$ ) in terms of CF density. In figure 5 Mean of collagen fiber density (%) for all groups in each healing period



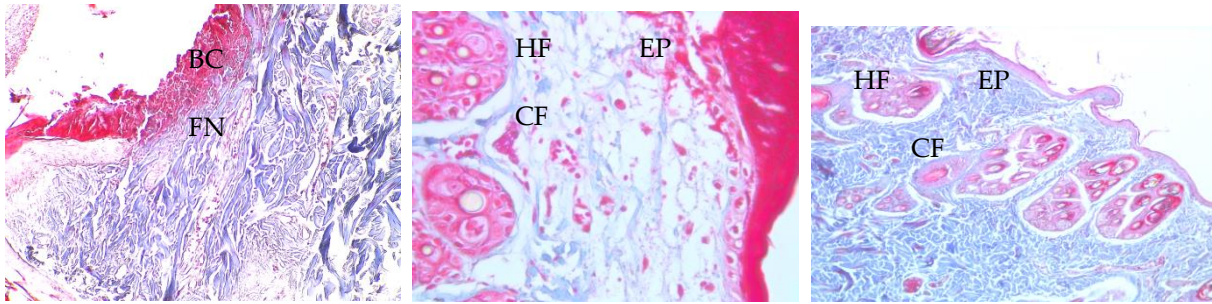


Figure 1: Control group: a) 3 days, b) 7days, and c) 14 days

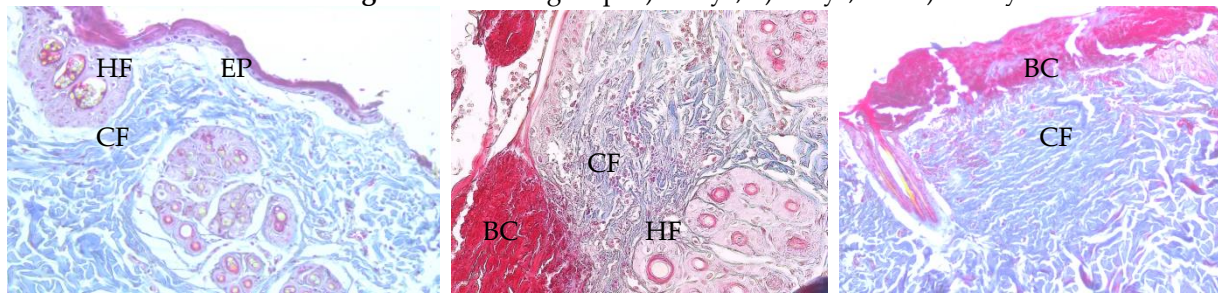


Figure 2: Experimental groups, day 3: a) OFI, b) PGS oil, and c) FOI/PGS

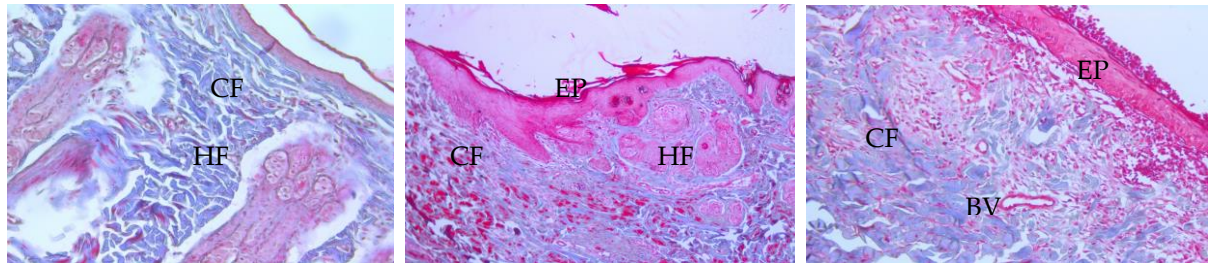


Figure 3: Experimental groups, day 7: a) OFI, b) PGS oil, and c) OFI/PGS

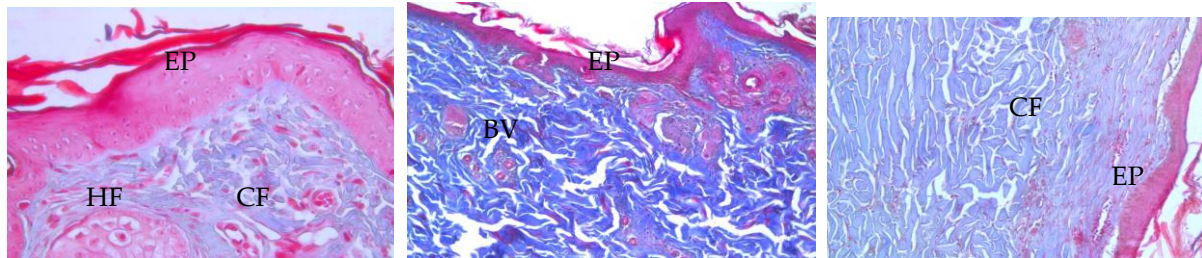
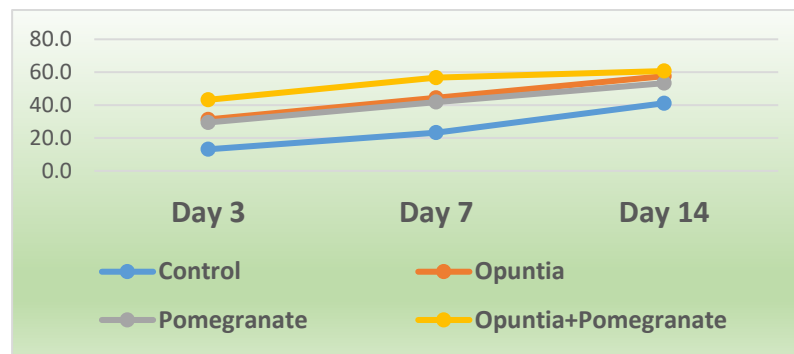


Figure 4: Experimental groups, day 14: a) OFI, b) PGS oil, and c) OFI/PGS group

Table 1: Descriptive statistics of collagen fiber density (%) for all groups at different duration

Duration	Study group	N	Mean	SD	Range	F value	P value
3 Days	Control	8	13.1	1.4	11.2–15.9	9.217	0.003**
	OFI	8	31.3	1.3	24.9–40.0		
	PGS	8	29.4	2.9	25.5–33.8		
	OFI+PGS	8	43.2	4.4	39.8–49.7		
7 Days	Control	8	23.2	2.8	18.9–27.9	9.986	0.001**
	OFI	8	44.4	4.7	39.9–48.3		
	PGS	8	41.9	4.2	38.4–48.3		
	OFI+PGS	8	56.7	5.6	49.3–68.3		
14 Days	Control	8	41.1	4.1	35.5–47.9	5.733	0.014*
	OFI	8	57.6	6	53.8–62.0		
	PGS	8	53.3	5.3	42.7–62.5		
	OFI+PGS	8	60.7	6.2	51.4–71.7		

\*: Significant differences; \*\*: Highly significant differences.



**Figure 5:** Mean of collagen fiber density (%) for all groups in each healing period

## Discussion

Wound healing is a common biological process in the human body that occurs in four highly programmed and precise stages: hemostasis, inflammatory phase, proliferative phase, and remodeling phase<sup>9</sup>. All four stages must occur in the correct order for successful wound healing that involves multiple events, including complex interaction processes between cells and their mediators that are essential for wound healing<sup>(10)</sup>.

In a histochemical study of wound healing, several factors are considered to determine the stage of changes. These factors include the depth and length of the healed wound, the epithelialization period, the infiltration of white BCs, the formation of elastin, and the aggregation of fibroblasts. However, CF remains the most significant factor because it is crucial to maintaining the anatomic integrity of wound healing. Collagen, which confers all tissues' strength and integrity, must be repaired when tissues are damaged as a result of injury to restore the anatomic structure and function of healing<sup>(11)</sup>. Collagen plays a vital role in maintaining the biological and structural integrity of the ECM and tissue function<sup>(12)</sup>. In the proliferative stage of the wound-healing process, the secretion of a specific form of collagen increases at the site of the damage to replace necrotic tissue with fibroblast cells, which are in charge of producing and synthesizing collagen protein in the skin<sup>(13)</sup>. As can be noticed in the histological section of the study, the experimental groups entered the remodeling phase earlier than the control groups, consistent with a prior study (Al-Mobeeriek, 2011)<sup>(14)</sup>. The present study aimed to determine the effect of FOI and PGS oils separately and in combination because both of them exerted anti-inflammatory effects, as well as to evaluate their effect by assessing CF density throughout the studied durations. They can reportedly prevent cutaneous infections, offer antioxidant protection from free radicals, and have anti-inflammatory and antimicrobial properties, as explained by Khémiri (2019; Uzunhisarckl, 2022)<sup>(15, 16)</sup>.

The experimental groups showed higher collagen densities than the control groups, consistent with earlier research (Kamil, 2019)<sup>(17)</sup>. On days 3, 7, and 14, we discovered that the experimental groups had more collagen density than the control group, consistent with previous studies (Enoch and Leaper, 2007; Reinke and Sorg, 2012)<sup>(18,19)</sup>. The current work revealed that re-epithelialization occurred more quickly in the experimental groups<sup>(20)</sup>. They also increase the proliferation and progression of epidermal cells, in agreement with the findings of Al-Mobeeriek (2011)<sup>(14)</sup>. As aforementioned, given that collagen restores the skin's integrity, collagen measurement and organization are crucial to investigations on wound healing. For accurate interpretations of wound healing, which are lacking in conventional hematoxylin and eosin staining, alternative staining techniques are crucial. Such techniques include modified Masson's trichrome staining and the use of computerized software to evaluate the collagen color intensity<sup>(13)</sup>. Formation Collagen is a major extracellular matrix protein and participate in wound closure<sup>(21,22)</sup>.

## Limitations

This study has one limitation; it prevented the rabbits from licking the wounds when we were placing the oils daily on their dorsal sides.

## Conclusion

The collective application of FOI and PGS oils was successful in increasing fibroblast activity, as indicated by the increased density of CF deposition over the extended healing period.

**Conflicts of interest: None.**

## Author contributions

EB; study conception and design, data collection, Methodology. EBN; statistical analysis and interpretation of results. EB; original draft manuscript preparation. EBN; Writing - review & editing. Supervision. All authors reviewed the results and approved the final version of the manuscript to be published.

## Acknowledgment and funding

The cooperation of the staff at the College of Dentistry / University of Baghdad is appreciated, no financial support was received for this study

## Informed consent

The study was approved by the College of Dentistry/University of Baghdad's local ethics commission (project No. 681722, Ref. number: 681).

## References

1. Sodagar A, Akhoundi MS, Bahador A, Jalali YF, Behzadi Z, Elhaminejad F, et al. Effect of TiO<sub>2</sub> nanoparticles incorporation on antibacterial properties and shear bond strength of dental composite used in Orthodontics. *Dent Press J Orthod.* 2017; 22(5): 67–74.
2. Ahmed AQ. The influence of titanium dioxide nanoparticles (TiO<sub>2</sub>NPS) incorporation into heat cured soft denture lining material on *Candida albicans* adherence and some other properties. M.Sc thesis. University of Baghdad, Iraq, 2018..
3. Ali SH, Ban A. Ghani, Kamil NB. In Vivo Histological Assessment of the Local Application of Fenugreek Seed Oil on Cutaneous Wound Healing. *Medico Legal J.* 2022; 22(2): 167–175. ([Crossref](#))
4. Conceição M, Gushiken LF, Aldana-Mejía JA, Tanimoto MH, Ferreira MV, Alves AC, et al. Histological, Immunohistochemical, and Antioxidant Analysis of Skin Wound Healing Influenced by the Topical Application of Brazilian Red Propolis. *Antioxidants J.* 2022; 11(11): 2188. ([Crossref](#))
5. Pastar I, Stojadinovic O, Yin NC, Ramirez H, Nusbaum AG, Sawaya A, et al. Epithelialization in Wound Healing : a comprehensive review. *Advances in Wound Care J.* 2014; 3(7): 445–464. ([Crossref](#))
6. Ibrahim NI, Wong SK, Mohamed IN, Mohamed N, Chin KY, Ima-Nirwana S, et al. Wound Healing Properties of Selected Natural Products. *International journal of Environmental Research and Public Health.* 2018; 15(11): 2360. ([Crossref](#))
7. Zare M, Shaverdi H, Ebrahimi Vosta Kalae S. Anti-cancer Effects of Pomegranate Seed Oil on Esophageal Cancer Cell Line (KYSE-30) Gene, Cell and Tissue J. 2021; 8(1):e108995. ([Crossref](#))
8. Mohamed IF, Ghani BA, Fatalla AA. Histological Evaluation of the Effect of Local Application of Punica Granatum Seed Oil on Bone Healing, *Inter J Biomat.* 2022 ID 4266589. ([Crossref](#))



9. Koshak AE, Algandaby MM, Mujallid MI, Abdel-Naim AB, Alhakamy NA, Fahmy UA, et al. Wound Healing Activity of Opuntia ficus-indica Fixed Oil Formulated in a Self-Nanoemulsifying Formulation, Inter J Nanomed. 2021; 16; 3889–3905 [\(Crossref\)](#)
10. Adwas AA, Elsayed A, Azab AE, Quwaydir FA.. Oxidative stress and antioxidant mechanisms in the human body , Applied Biotechnology and Bioengineering J. 2019; 6(1): 43–47. [\(Crossref\)](#)
11. Al-Wattar WM, Abdullah BH, Mahmmud AS. Irradiation Effect of 780–805 nm Diode Laser on Wound Healing in Mice, J Bagh Coll Dent. 2014; 25 (Special Issue):48–52.
12. Ghani BA .Histological Evaluation of the Effect of Topical Application of Curcumin Powder and Essential Oil on Skin Wound Healing, J Bagh Coll Dent. 2015; 27 (3), 58–63. [\(Crossref\)](#)
13. Majeed AA, Abood DA ,Histological assessment of the efficiency of rabbit serum in healing skin wounds. Veterinary World J, 2019; 12(10): 1650-1656. [\(Crossref\)](#)
14. Aszodi A, Legate KR, Nakchbandi I, Fässler RJ, What mouse mutants teach us about extracellular matrix function, Annual rev cell develop bio, 2006; 22, 591–621. [\(Crossref\)](#)
15. Suvik A, Effendy AW. The use of modified Masson's trichrome staining in collagen evaluation in a wound healing study , Malaysian Journal of Veterinary research. 2012; 3: 39-47. [\(Crossref\)](#)
16. Al-Mobeeriek A. Effects of myrrh on intra-oral mucosal wounds compared with tetracycline- and chlorhexidine-based mouthwashes. Clin Cosmet Investig Dent. 2011;3:53-58 [\(Crossref\)](#)
17. Aszodi A, Legate KR, Nakchbandi I, Fässler RJ. What mouse mutants teach us about extracellular matrix function. Annu. Rev. Cell Dev. Biol.. 2006 Nov 10;22:591-621. [\(Crossref\)](#)
18. Uzunhisarckl E, Yerer M. Role of Hypericum perforatum oil and pomegranate seed oil in wound healing: an in vitro study, Zeitschrift für Naturforschung C. 2022; 77(5–6), 189–195. [\(Crossref\)](#)
19. Kamil NB, Al-Ghaban NM. Evaluation of effect of local exogenous application of Myrrh oil on healing of wound incisions of facial skin Histochemical, Histological and Histomorphometrical study in rabbits). J Bagh Coll Dent 2019;31(4). [\(Crossref\)](#)
20. Enoch S, Leaper, DJ. Basic science of wound healing. Surgery J. 2007; 26(2):31. [\(Crossref\)](#)
21. Reinke JM, Sorg H. Wound repair and regeneration. Eur Surgical Research J.2012; 49: 35-43 [\(Crossref\)](#)
22. Shaykhiev R, Beißwenger C, Kändler K, Senske J, Püchner A, Damm T, et al. Human endogenous antibiotic LL-37 stimulates airway epithelial cell proliferation and wound closure. Am J Physiol Lung Cell Mol Physiol. 2005; 289(5):842–848. [\(Crossref\)](#)
23. Smith KJ, Skelton HG, Barrett TL, Welch M, Beard J. Histologic and immunohistochemical features in biopsy sites in which bovine collagen matrix was used for hemostasis. J Am Acad Dermatol J . 1996; 34(3): 434-438. [\(Crossref\)](#)
24. Kang S, Jang EJ, Jo HM, Kang SS, Lee MS, Yun SY, et al. Effects of a Topically Applied Oral Wound Dressing Film on Intra-oral Wound Healing in Rabbits. In vivo (Athens, Greece). 2022; 36 (4) 1745–1752. [\(Crossref\)](#)

#### الاستخدام الموضعي لزيت التين الشوكي /الرمان على التئام الجروح الجلدية: دراسة نسيجية كيميائية إيناس يوسف الزبيدي , بان عبد الغني , نور روزياتي إبراهيم المستخلص:

الخلفية: الشفاء عملية تعيد السلامة الجسدية لهياكل الجسم. هي عملية ديناميكية ومعقدة ومتعددة الخلايا تتضمن المصفوفة خارج الخلية والسينوكينات وخلايا الدم وعوامل النمو. ويشمل الإرقاء ، والمرحلة الانتهاجية ، ومرحلة التكاثر ، ومرحلة النضج. زيت التين الشوكي وزيت بذور الرمان هو علاج طبيعي يستخدم على نطاق واسع ويعتبر مفيداً لخصائصه المهدئة والمضادة للتشنج والمضادة للالتهابات وكذلك لتعزيز تكوين الأوعية الدموية وتكاثر الخلايا الليفية وتخليق الكولاجين وترسبه. المصفوفة خارج الخلية الجديدة. المواد والطرق تم استخدام 32 أرنباً نيوزيلندياً. أجرى كل حيوان أربع جروح معيارية دائرية على ظهره بقطر خزعة معقمة (8 مم) ، وكان جرح التحكم في الجانب الأيمن العلوي يذهب للشفاء بشكل عام ، وتم وضع زيت التين الشوكي في الجانب الأيسر العلوي وتم وضع زيت الرمان المعالج في الجانب الأيمن السفلي وأخيراً الجانب الأيسر السفلي تمت معالجته بمزيج من زيتين زيت الرمان وزيت التين الشوكي للحيوانات في كل يوم إلى نهاية كل فترات الشفاء (اليوم الأول و الثالث والسابع والرابع عشر) ليتم بعدها جمع العينات عن طريق قطع الجلد حوالي 5 مم حول حواف الجرح لتقييم النسيج الكيميائي.

الخلاصة: زيت التين الشوكي الموضعي / زيت بذور الرمان مقارنةً بالسيطرة ، أظهر التطبيق تحسناً في التئام الجروح من خلال تعزيز تخليق كولاجين المصفوفة الخلاصة: أظهرت الدراسة الحالية أن تطبيق زيت التين الشوكي الموضعي / زيت بذور الرمان على الجروح الاستتصالية كان فعالاً في التئام الجروح عند استخدامه موضعياً.